

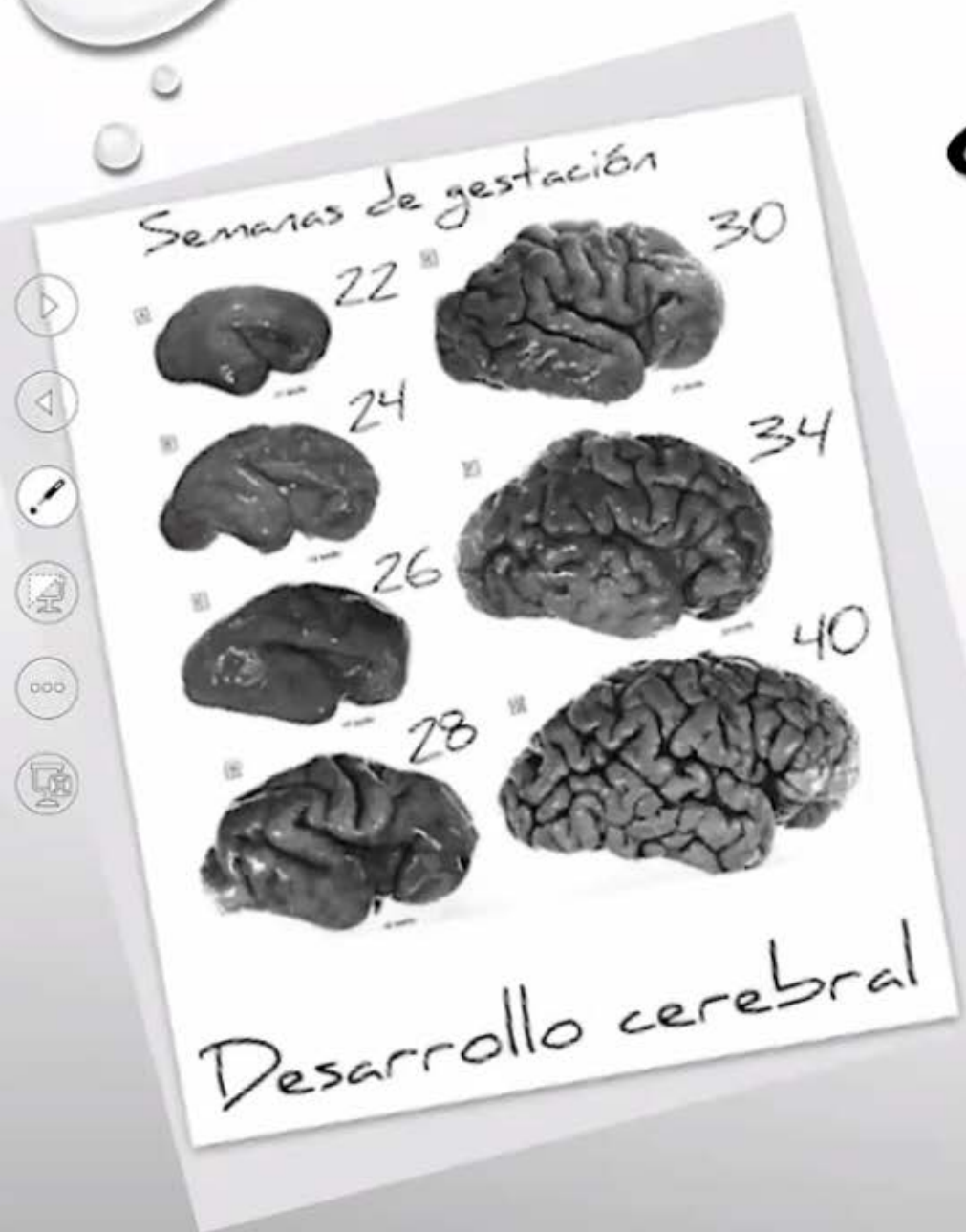
¿POR QUÉ SÍ A LA RM DE ENCÉFALO EN NEONATOS?

Dra. Alejandra Durán Bustamante

Neuropediatra U. de Chile

Servicio de Neonatología

H. Hernán Henríquez Aravena, Temuco



Ecografía

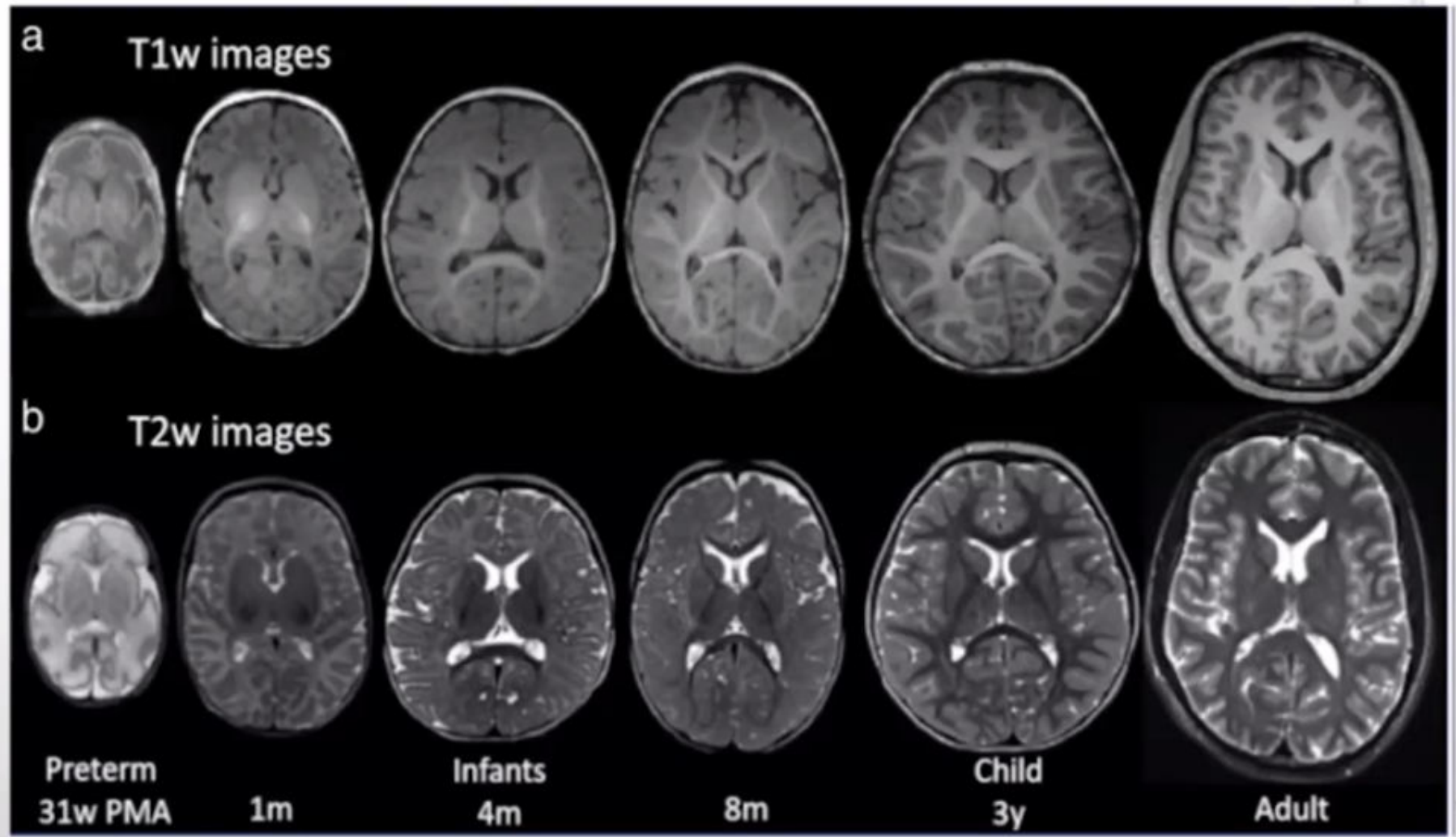
**Modalidad
Neuroimagen**

**Resonancia
Magnética**

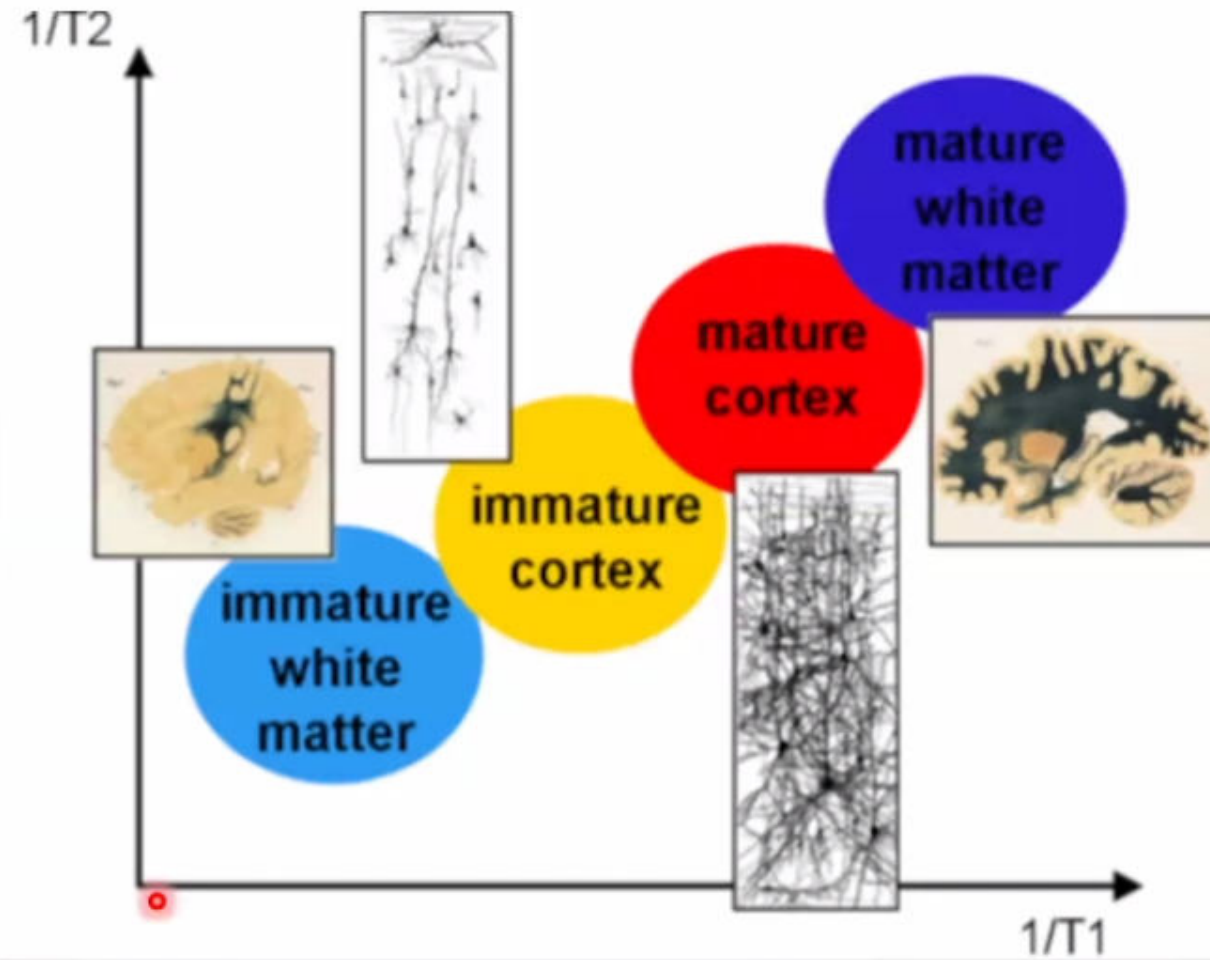
**Tomografía
Computarizada**

02:49

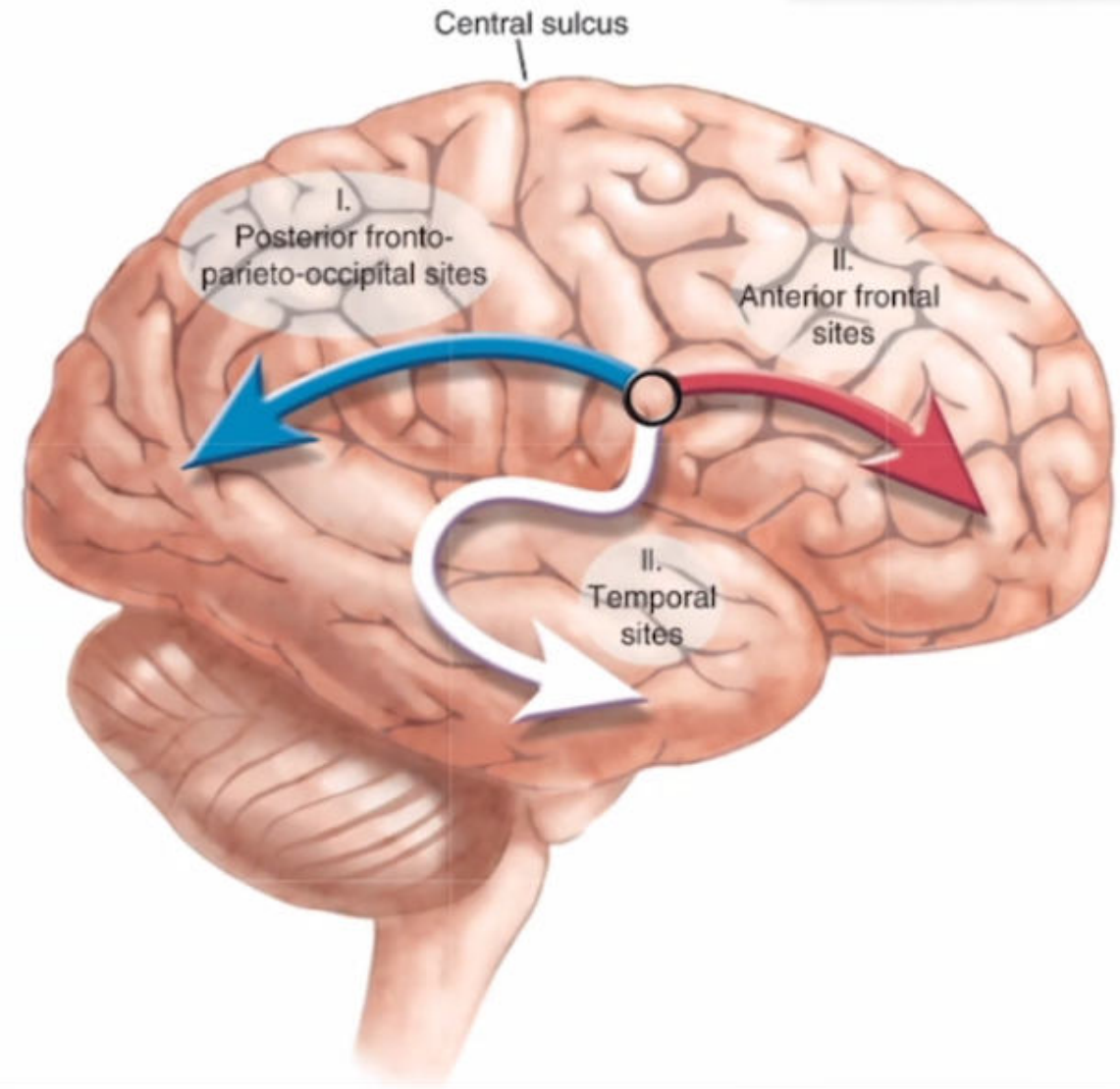
Secuencias estructurales



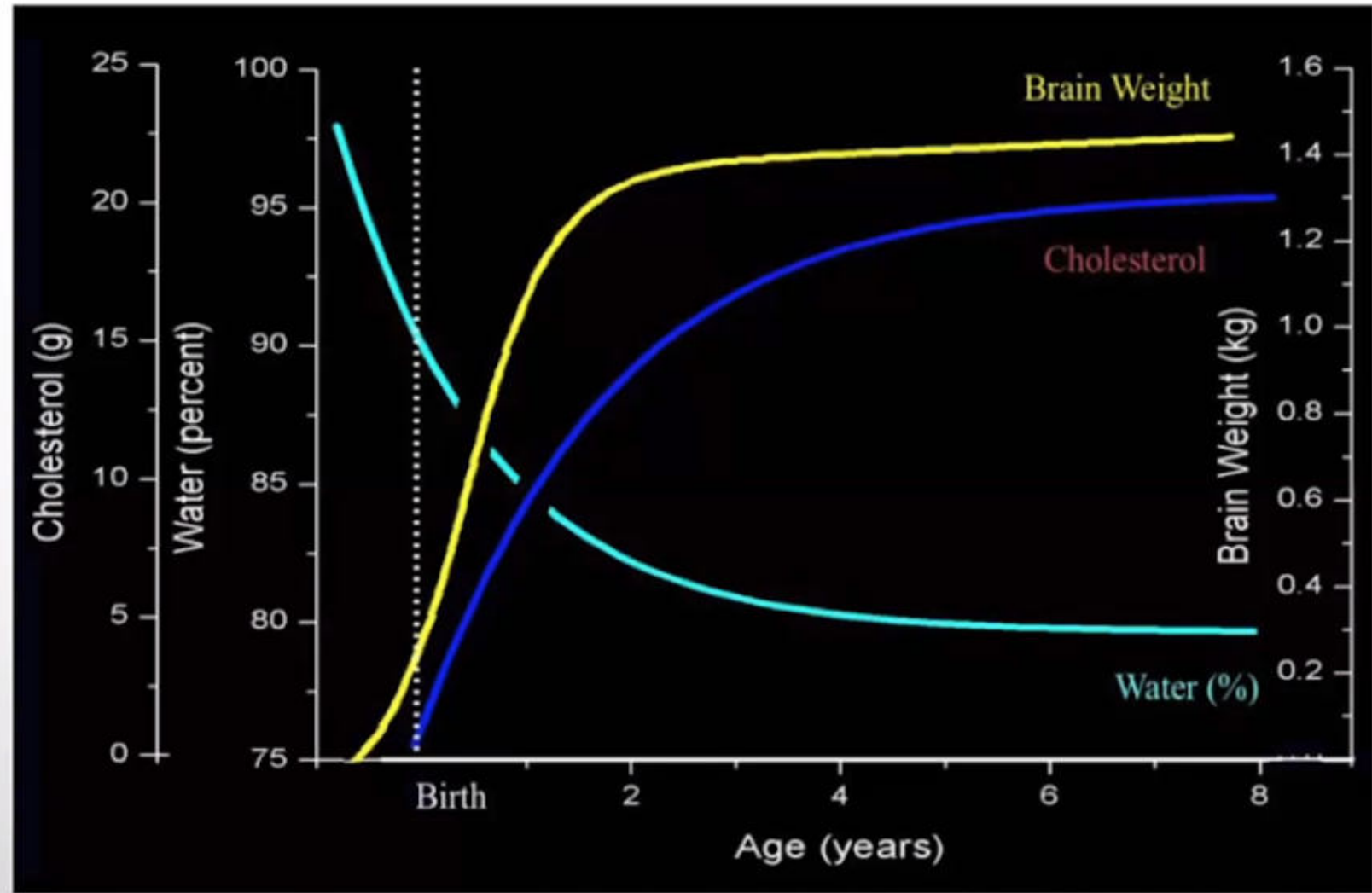
Proceso de maduración

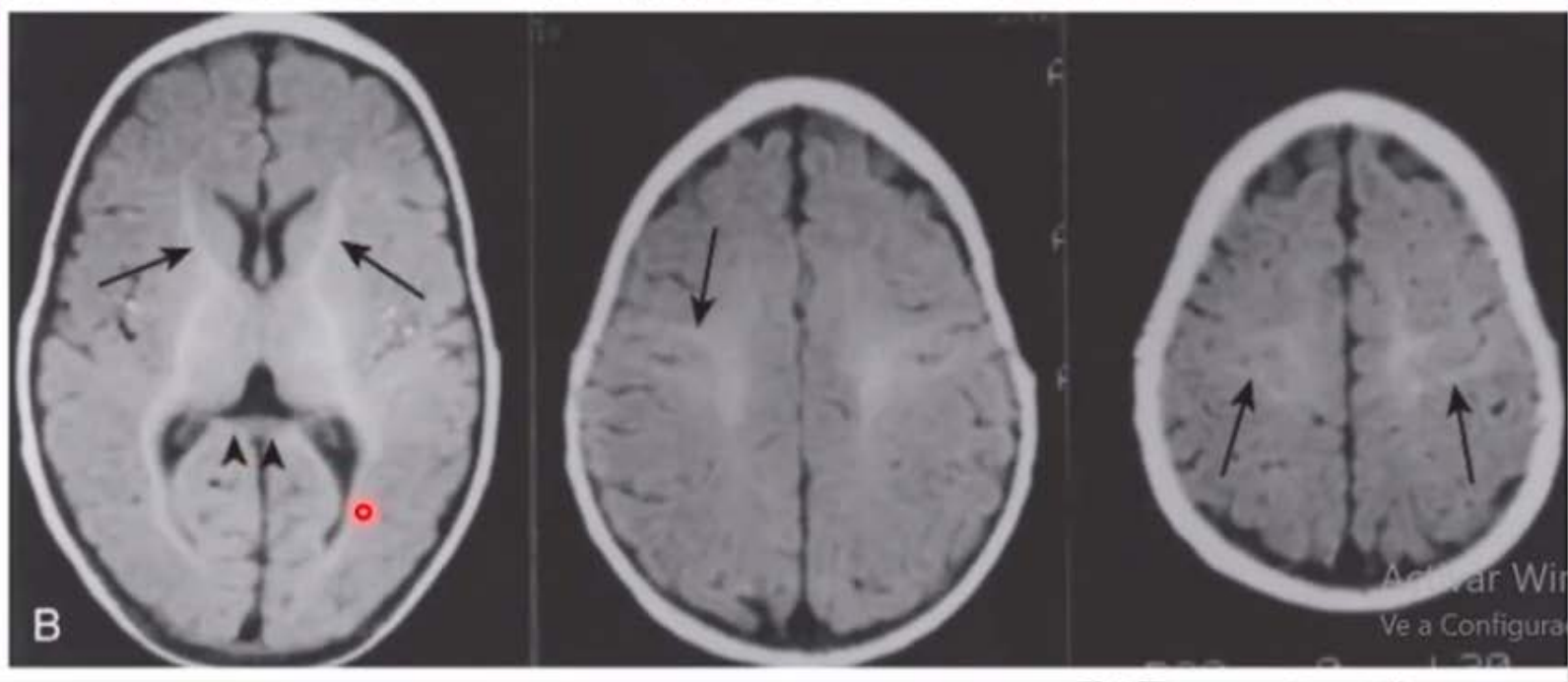
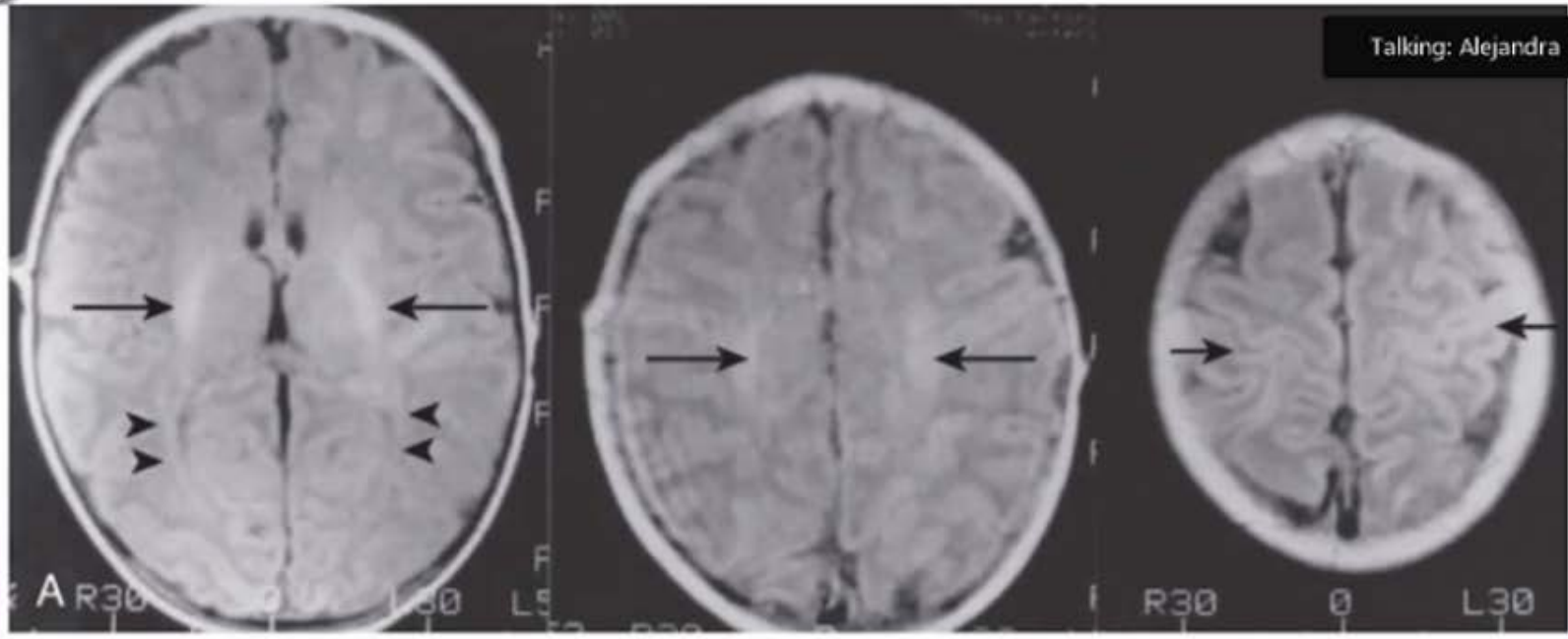


Proceso de mielinización



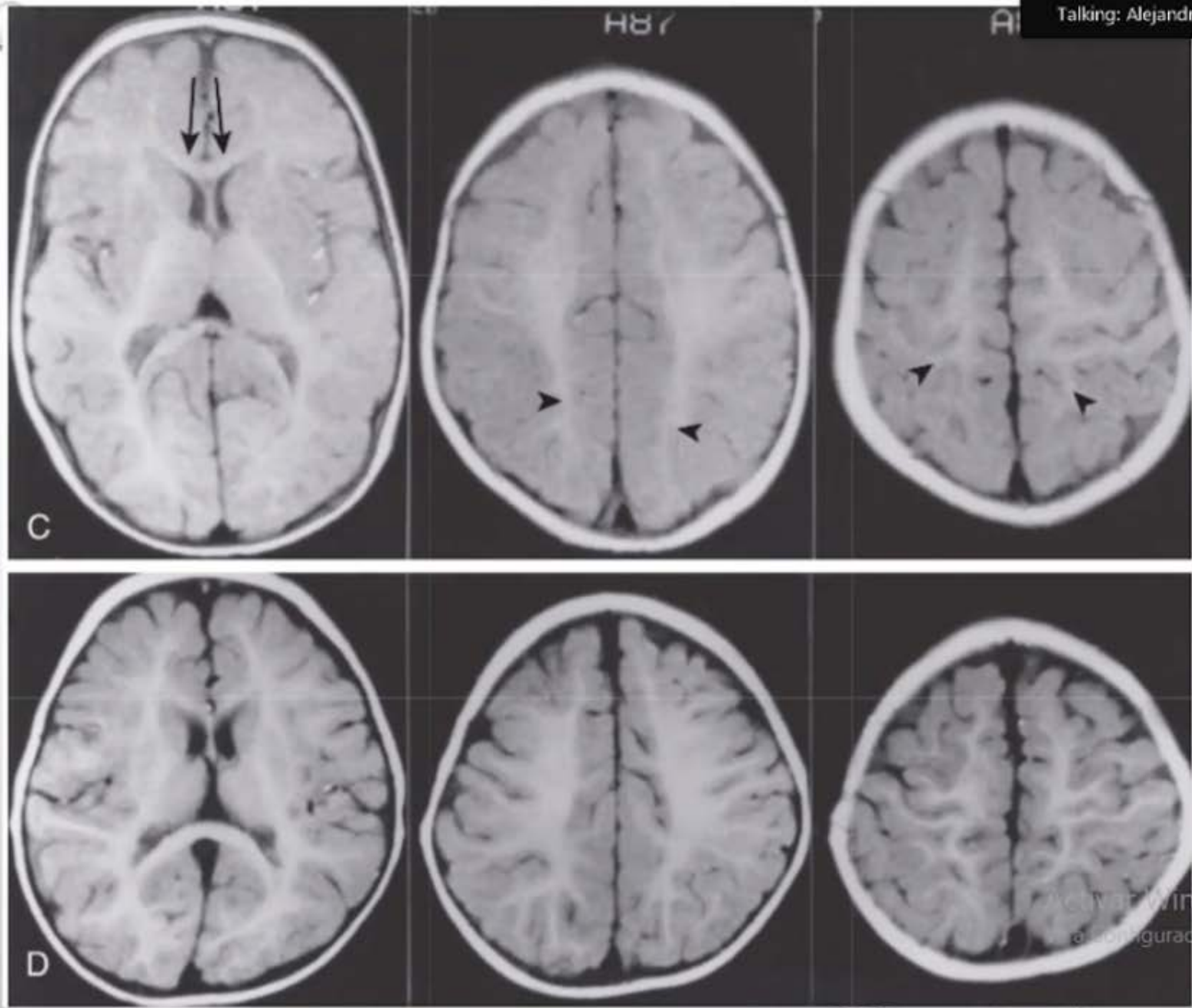Sumatoria procesos de maduración y mielinización





Ejemplo:
T1

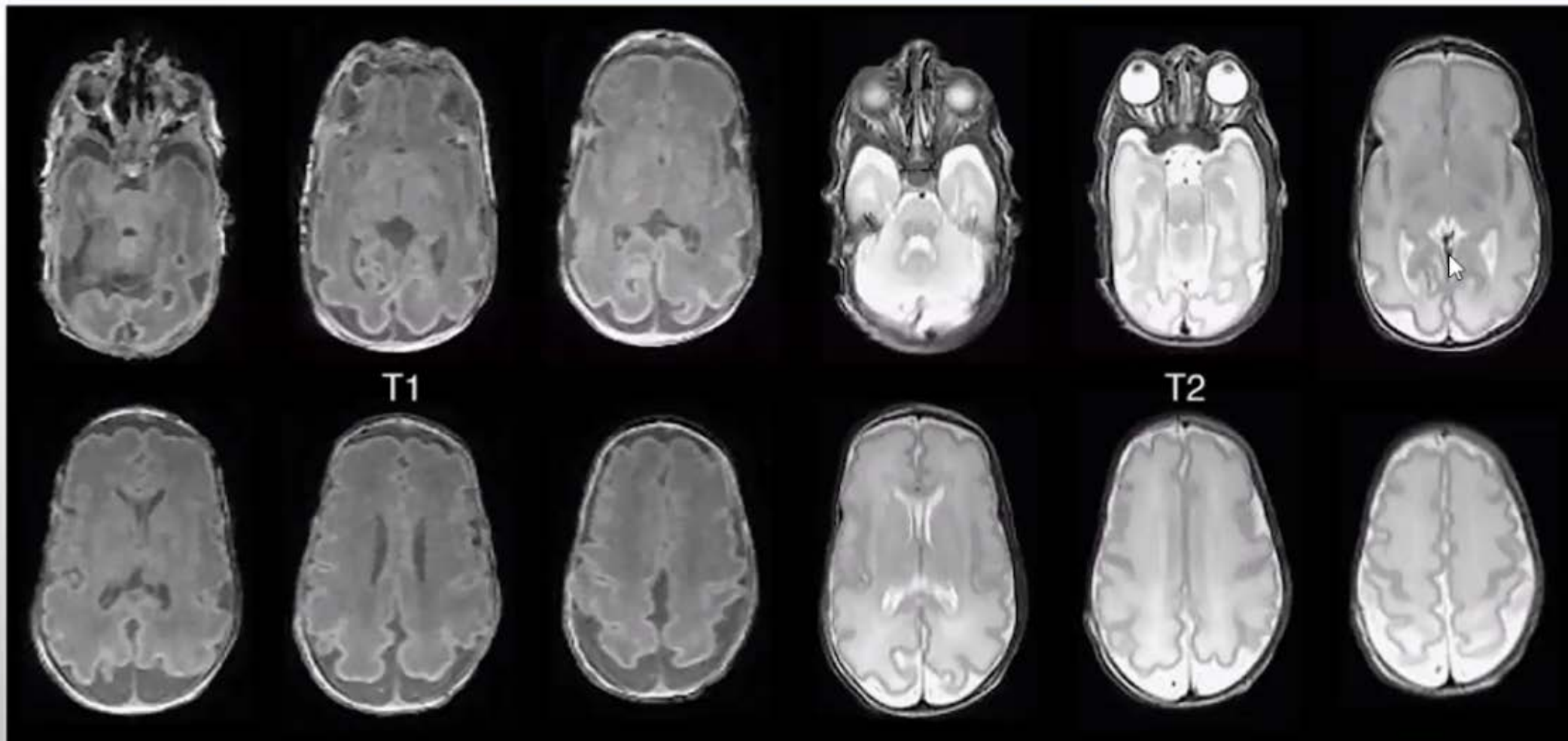




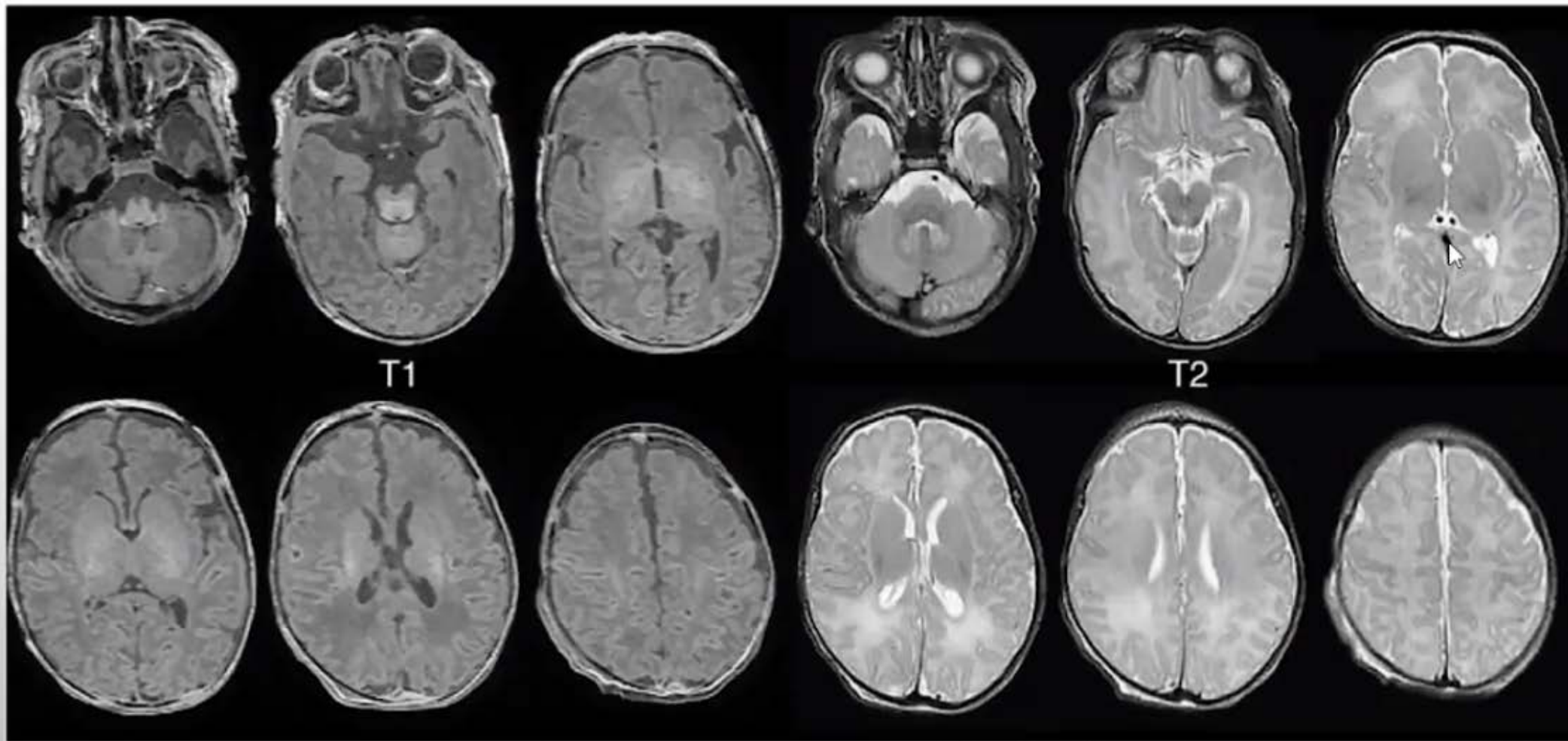
Ejemplo:
T1



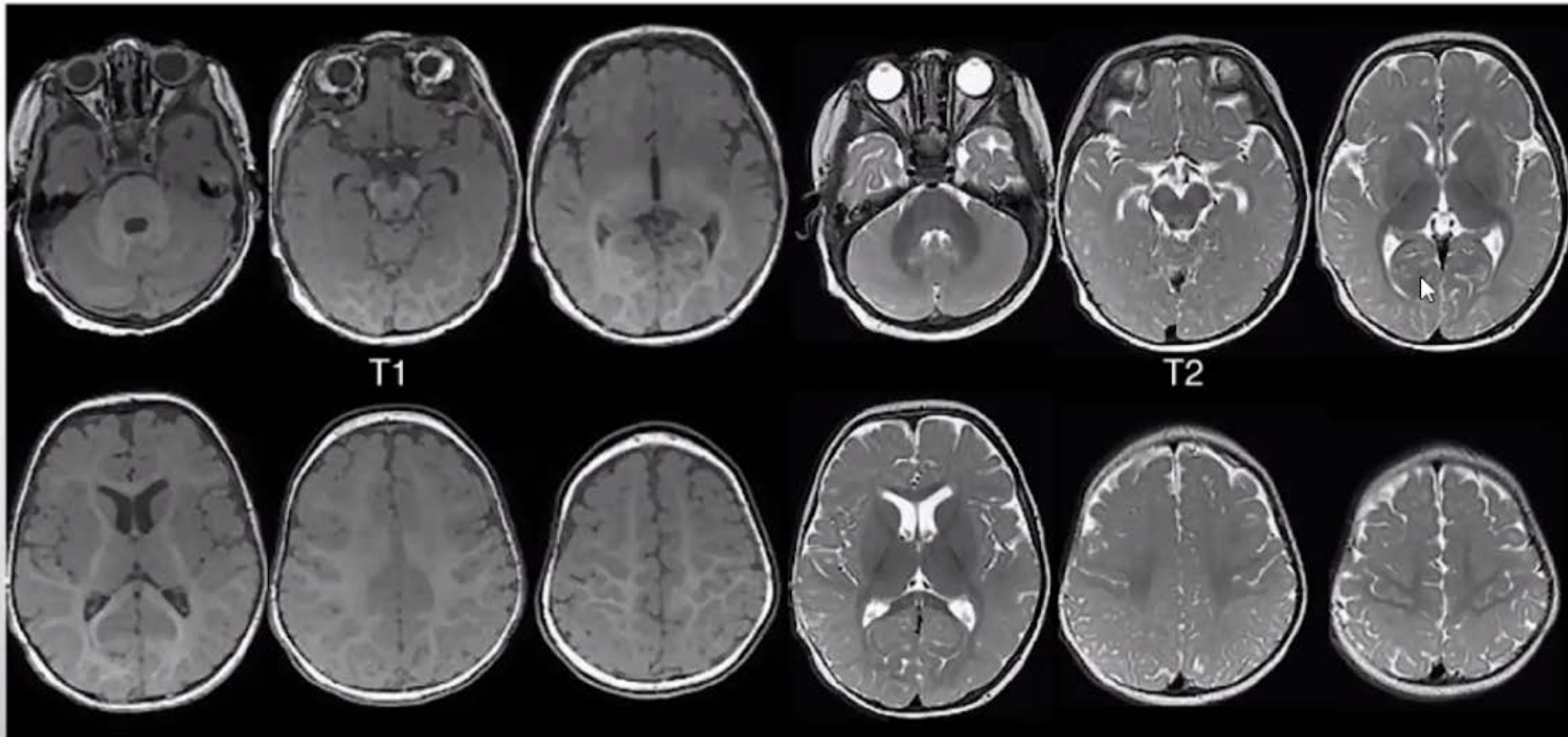
Ejemplo: RNPT 29 sem.



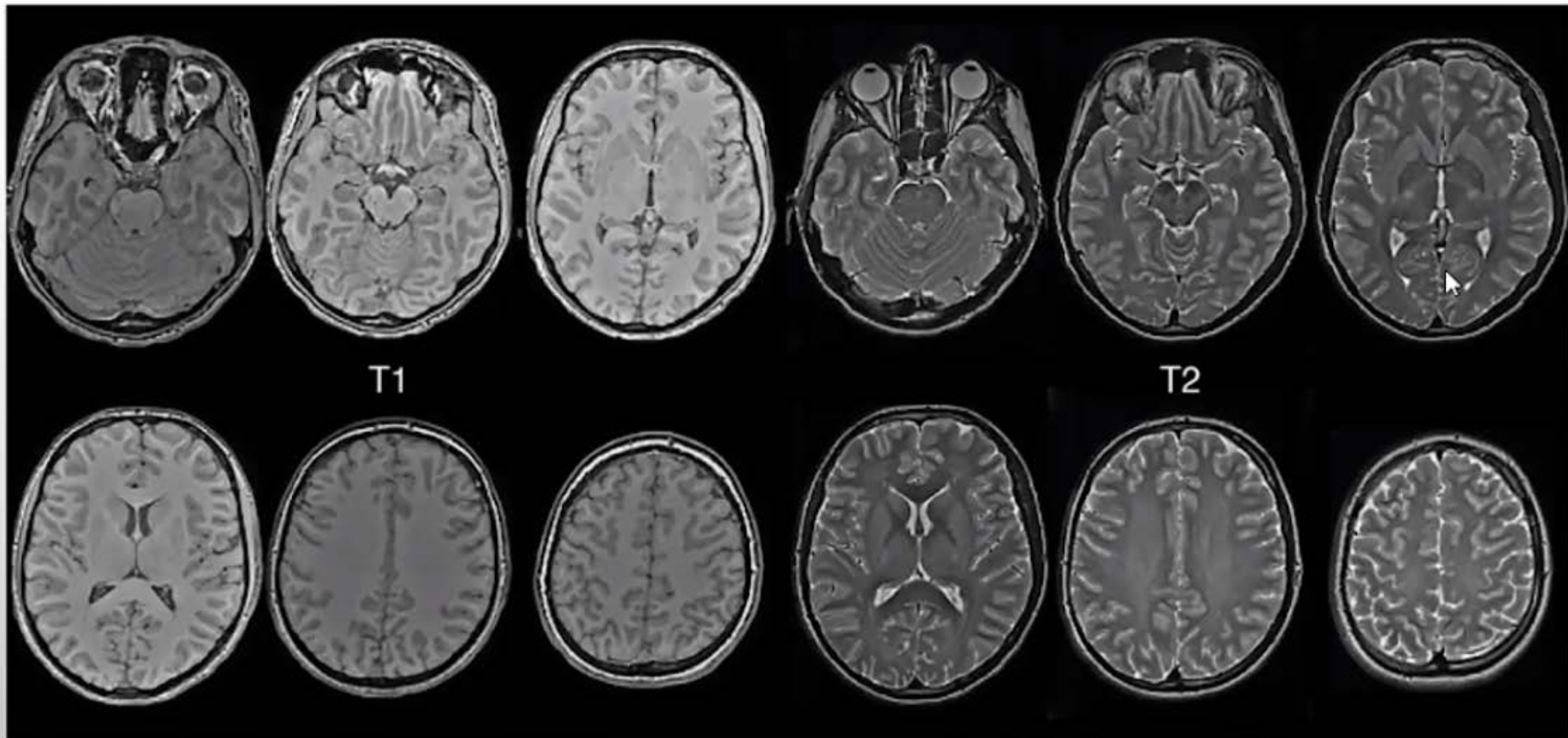
Ejemplo: RNT



Ejemplo: 6 meses

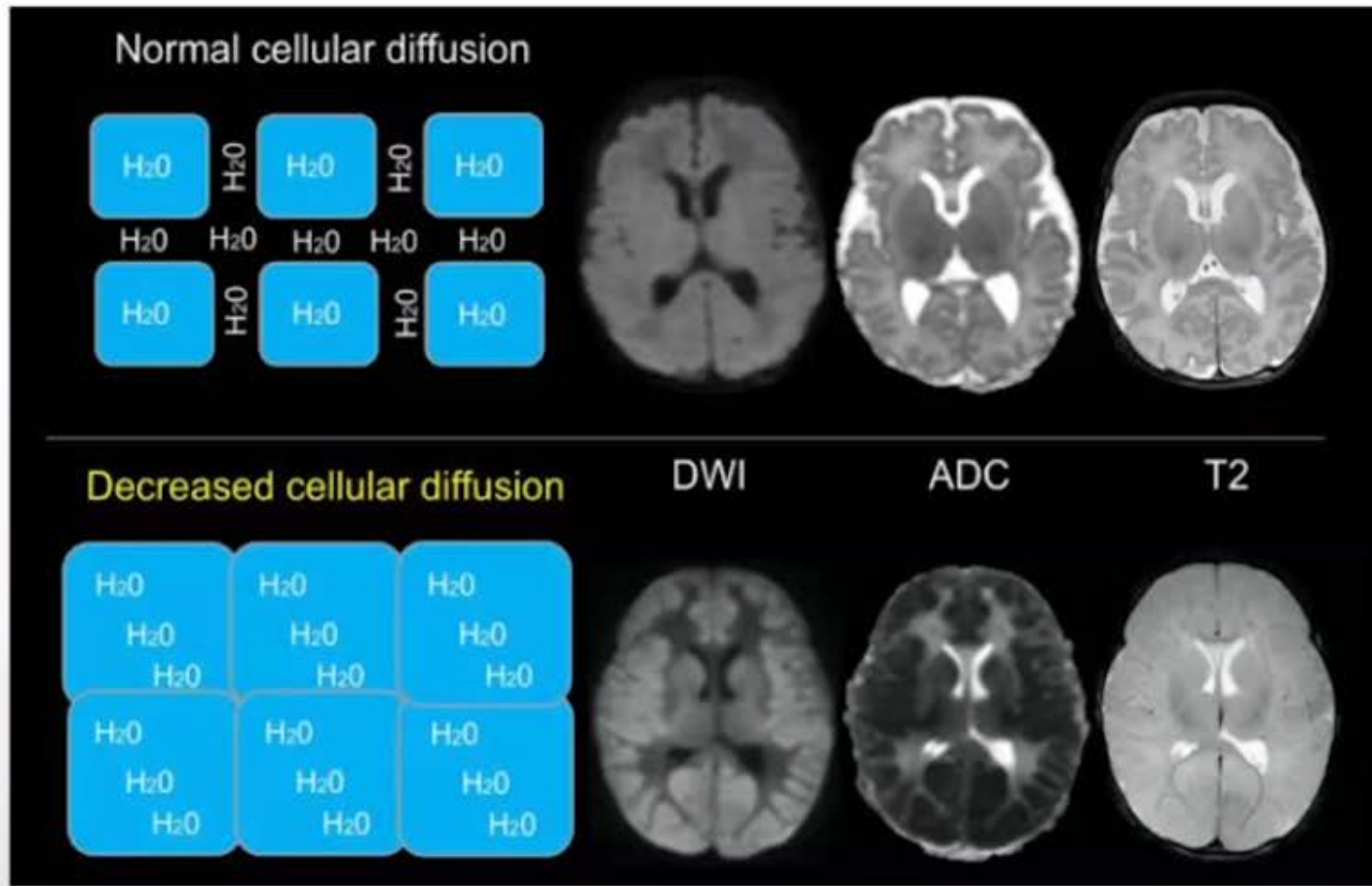


Ejemplo: 14 años

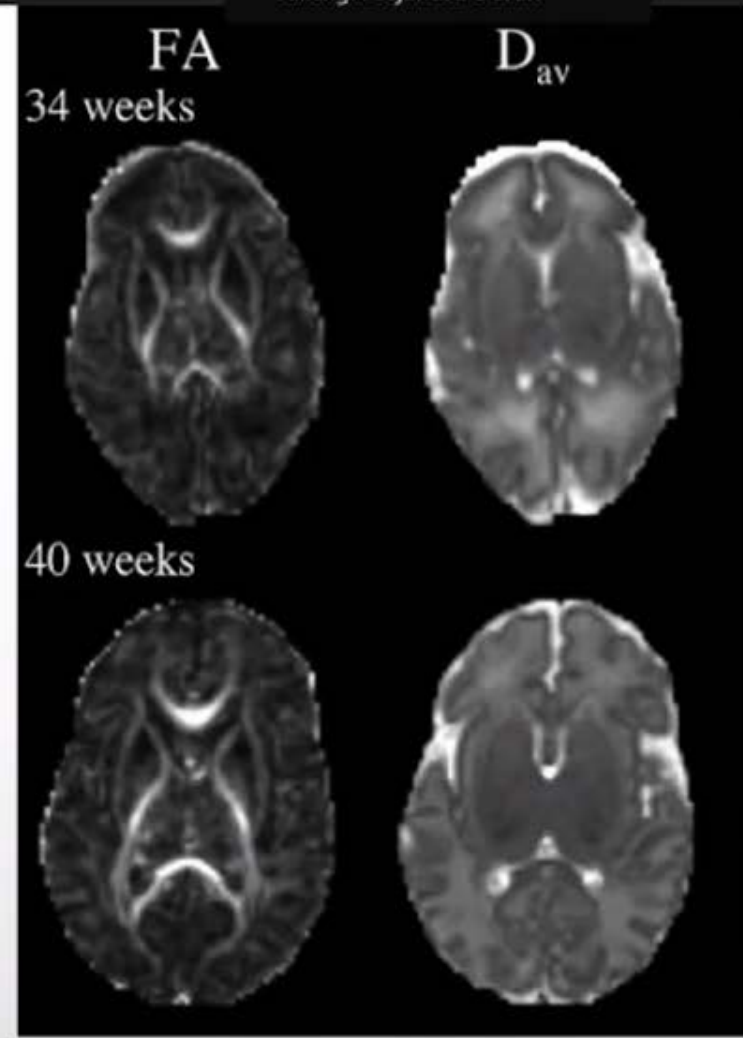
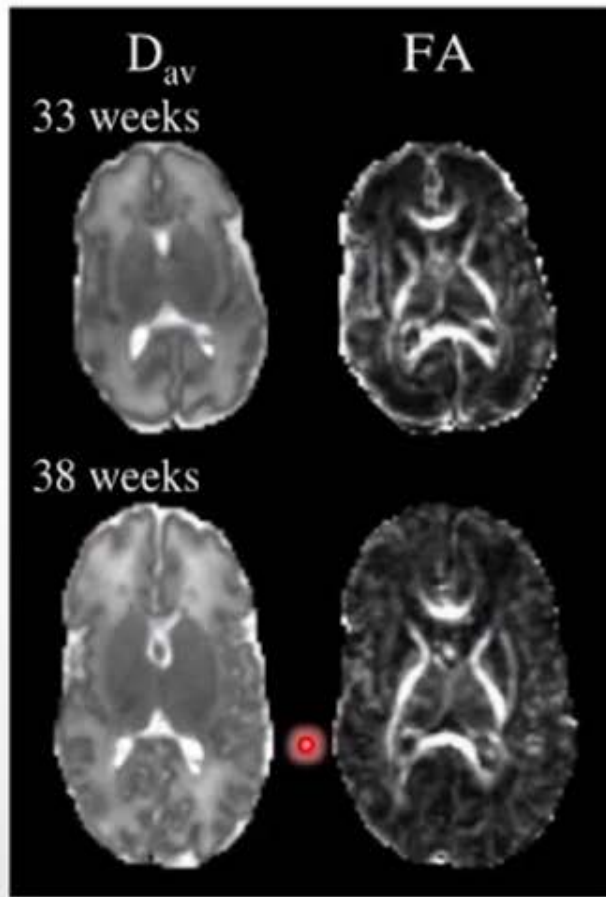


Secuencias diagnósticas

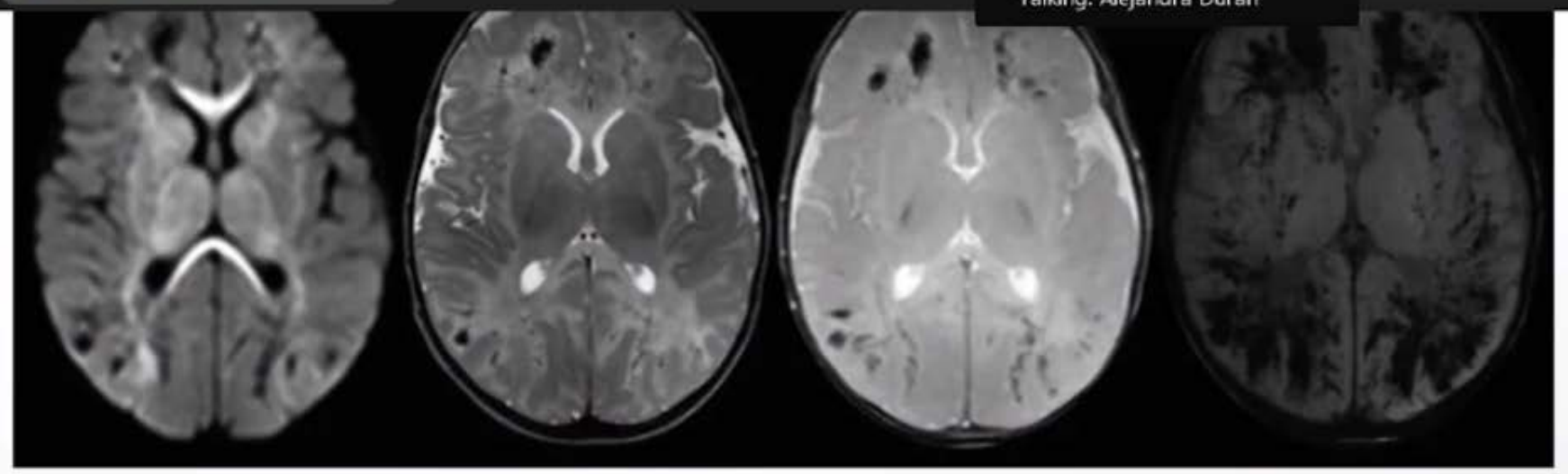
Difusión



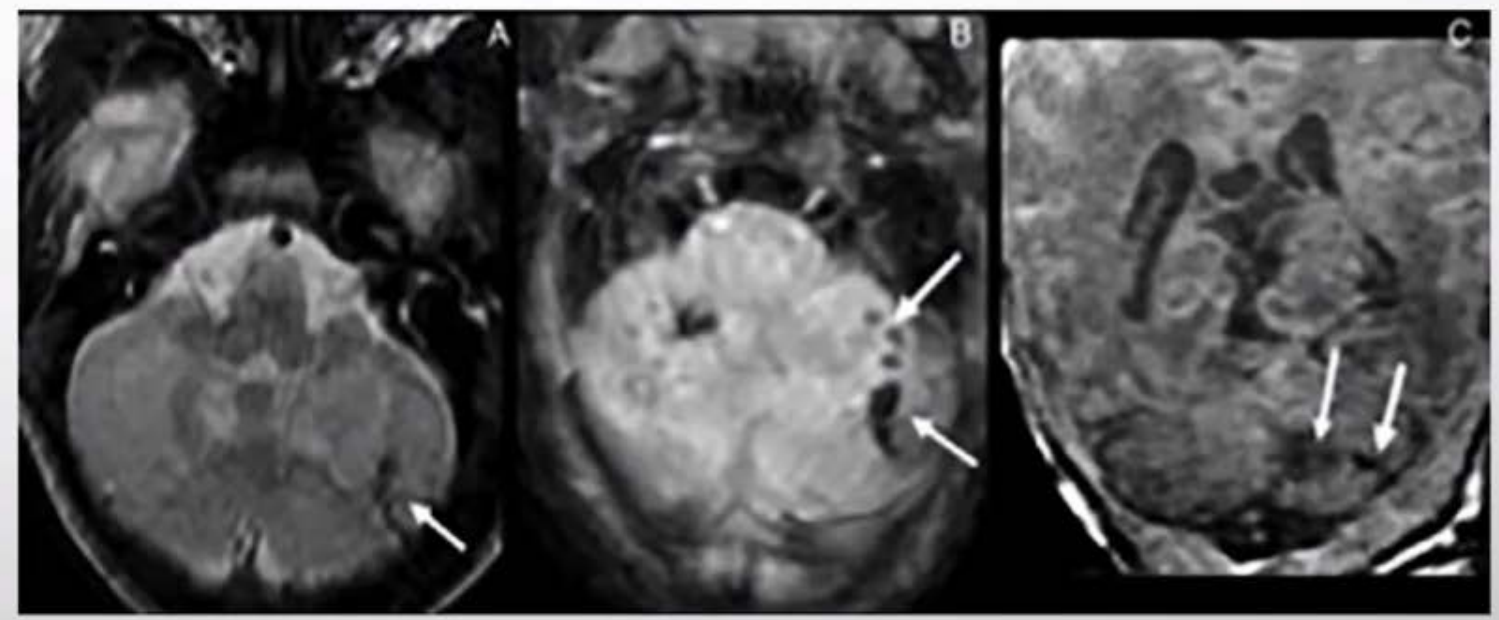
Difusión



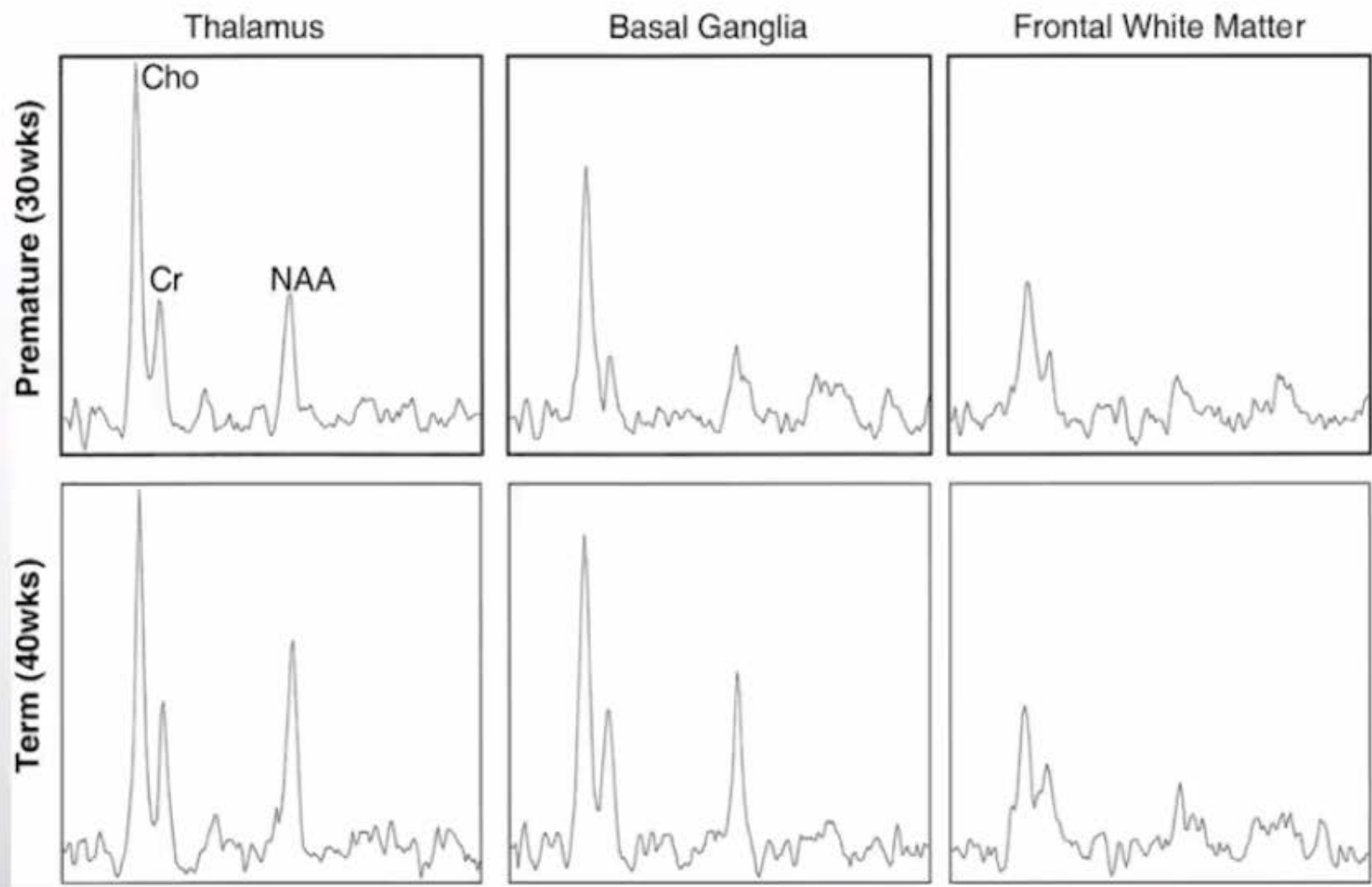
Secuencias diagnósticas



Susceptibilidad magnética



Espectroscopía

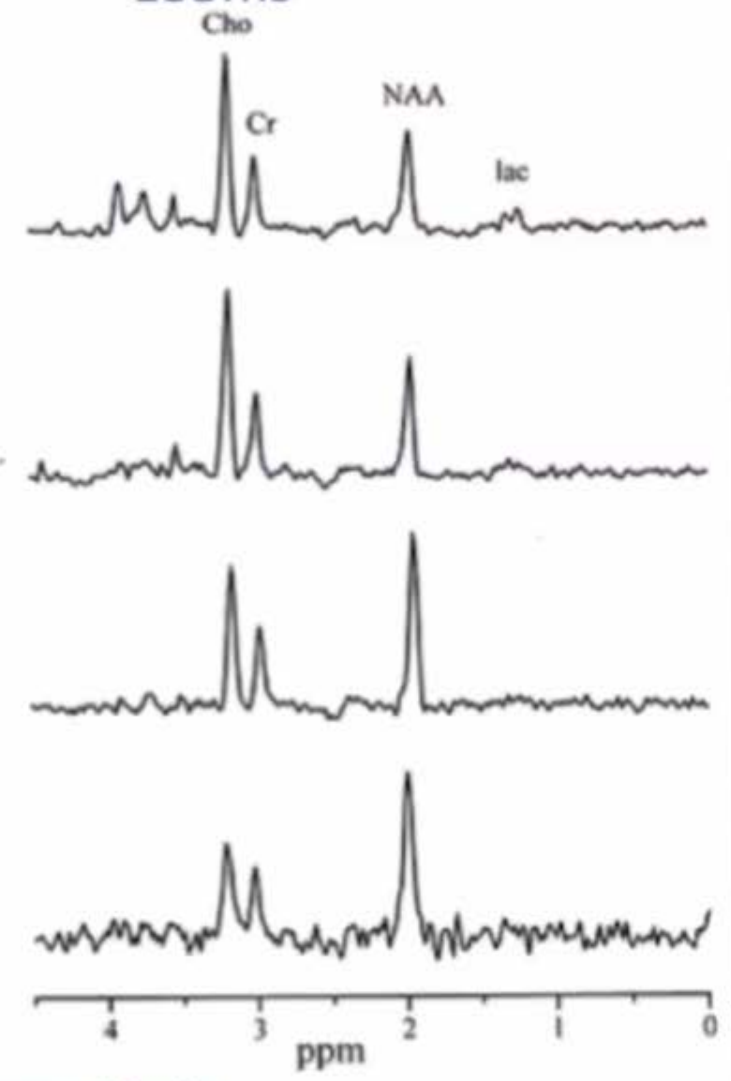
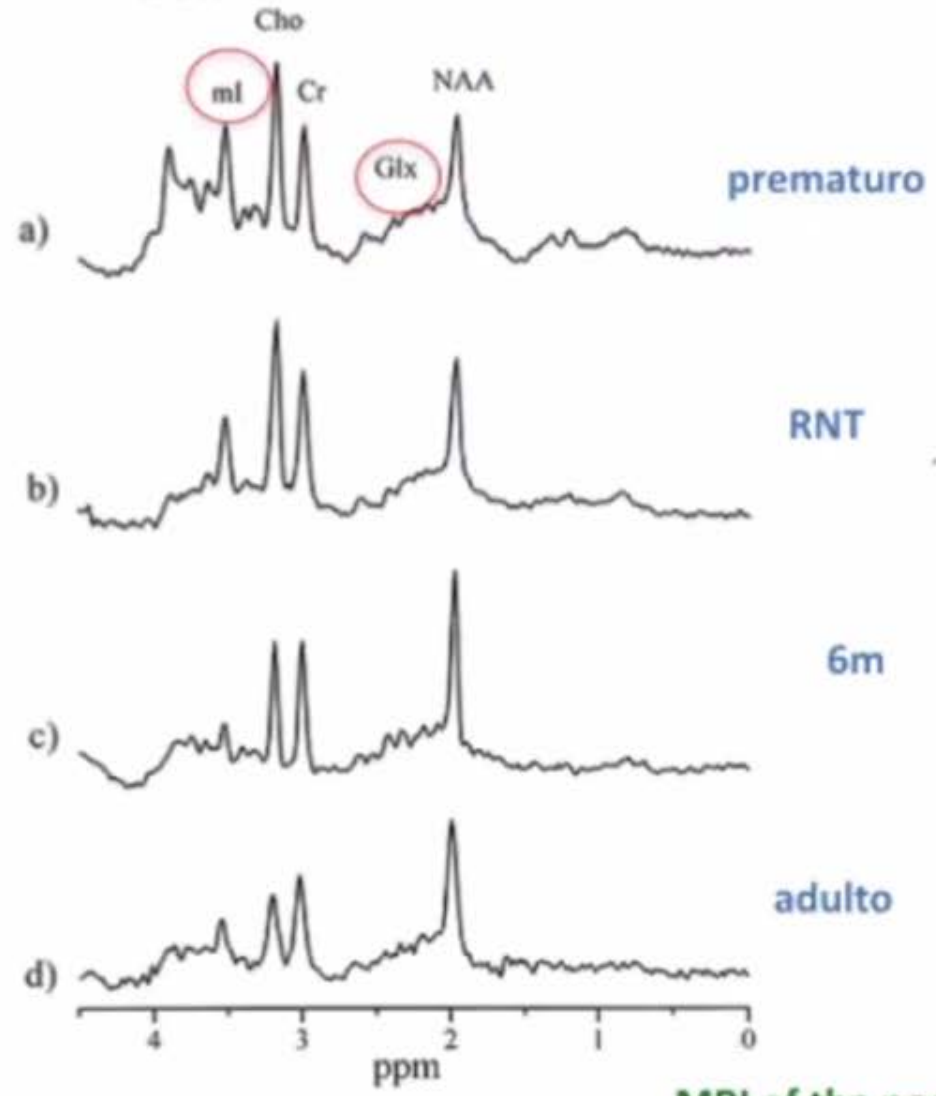


HMRS TE corto → metabolopatía

HMRS TE largo → Hipoxia-isq

35ms

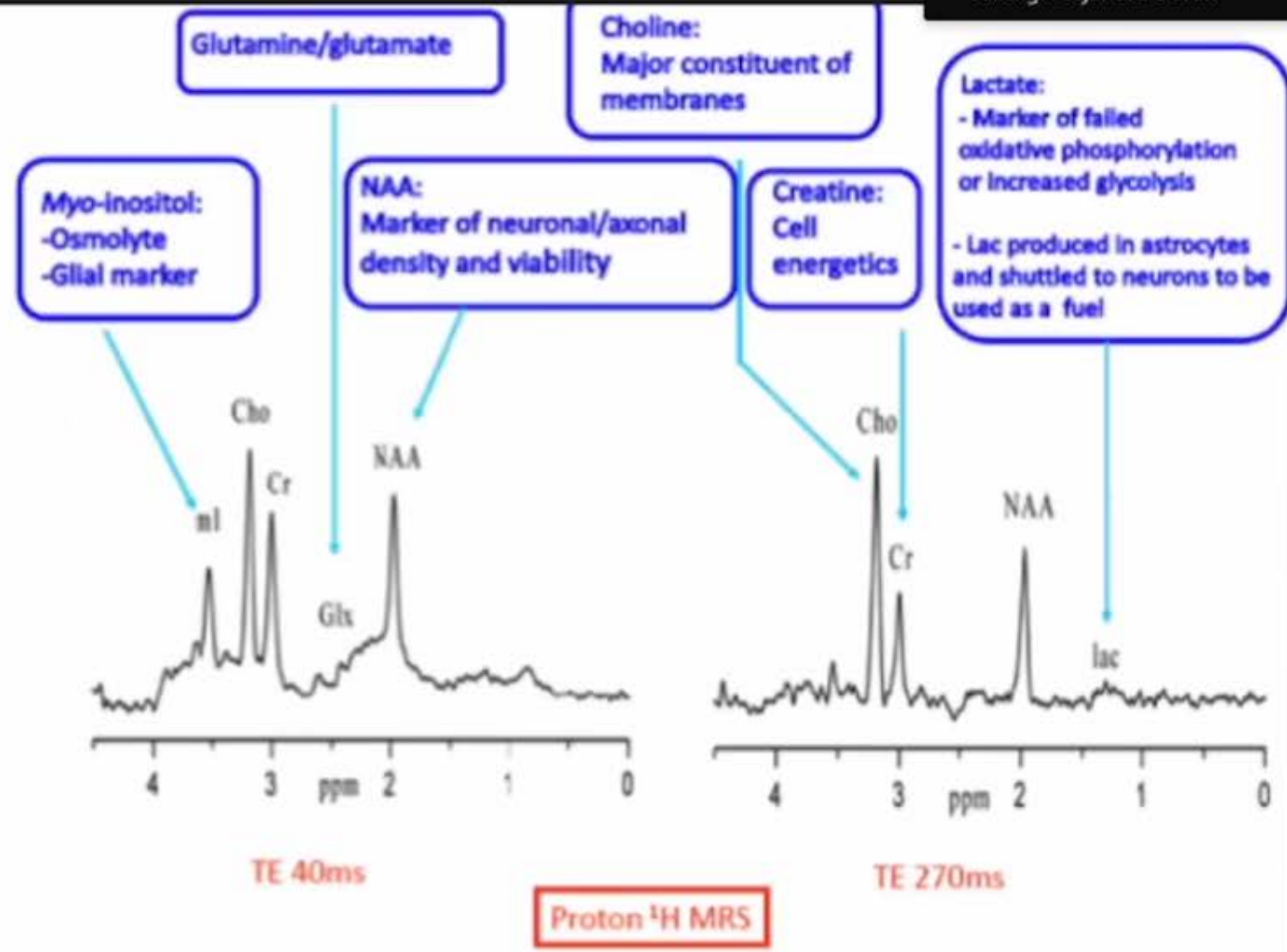
135ms



Espectroscopía

MRI of the neonatal brain

Espectroscopía



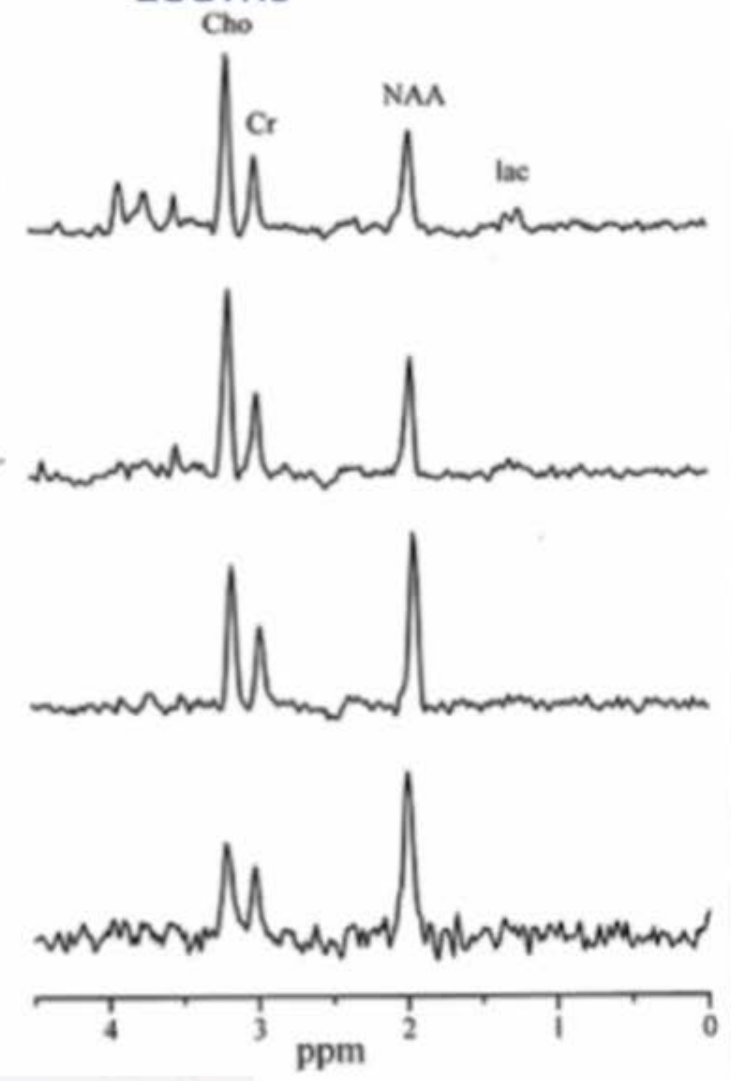
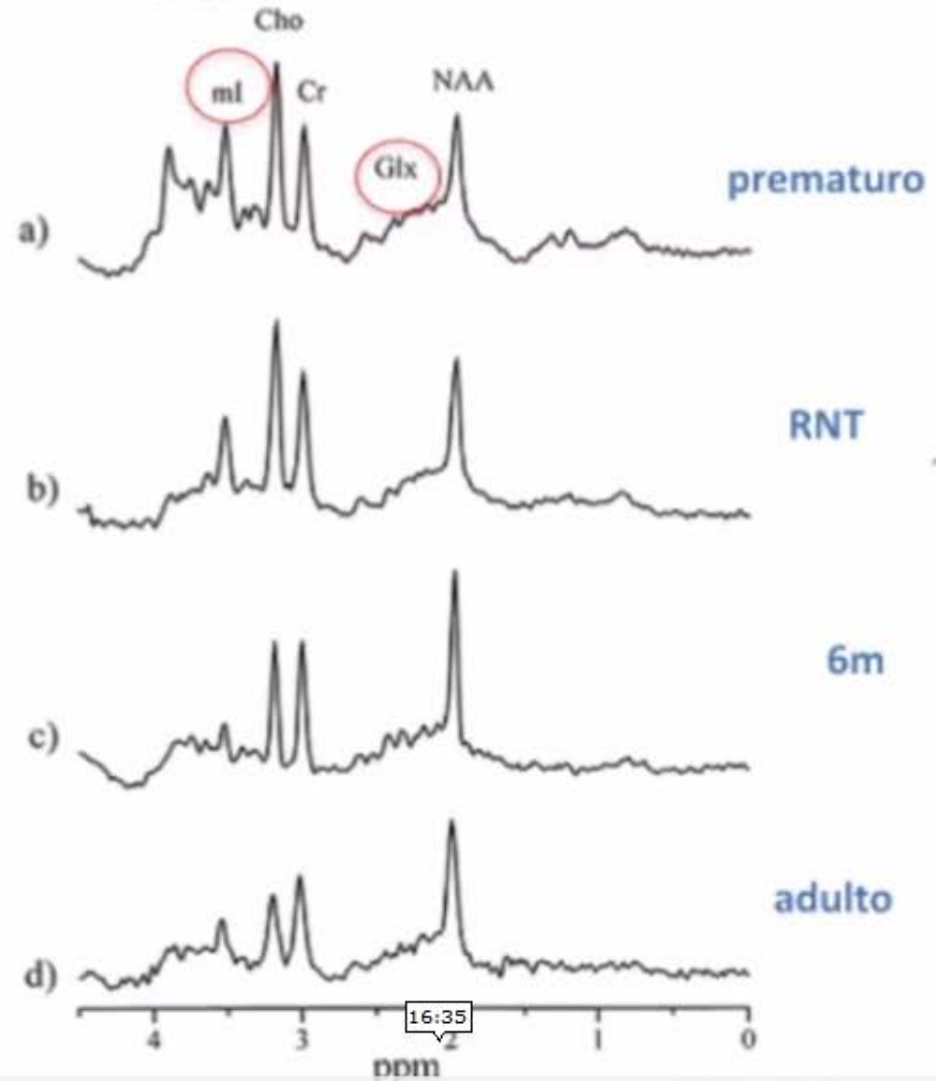
Robertson N. Curr Pediatr Rev 2014

HMRS TE corto → metabolopatía

HMRS TE largo → Hipoxia-isq

35ms

135ms



Espectroscopía

LECTURA



16:44 16:15 33:14

16:44/33:14 100%

A video player interface at the bottom of the screen. It features a horizontal progress bar with a blue segment on the left and a white segment on the right. Below the bar are several control buttons: a play/pause button, a previous button, a stop button, a next button, and a full screen button. On the right side, there is a volume control icon showing 100% and a tooltip above the progress bar indicating the current time is 16:15.

T1:

- Mielinización.
- Morfología.

T2:

- Diferenciación SB/SG.
- Edema/inflamación SB.

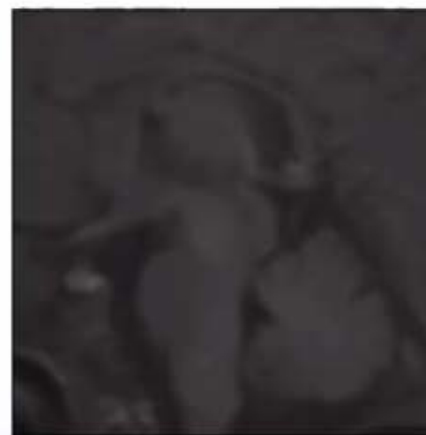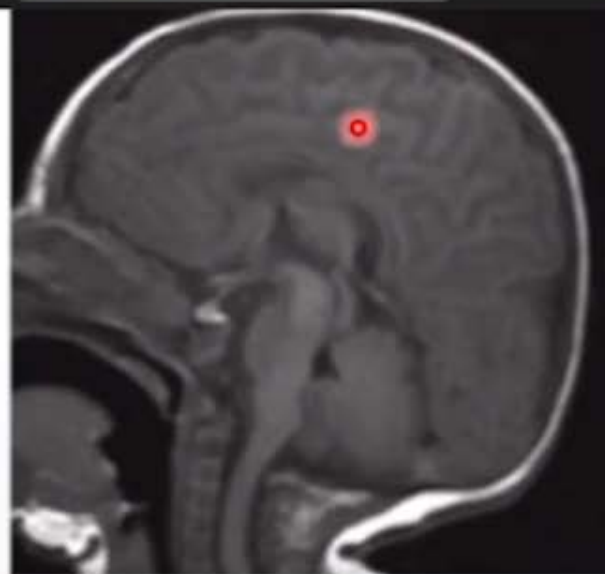**Secuencia
suscceptibilidad
magnética:**

- Hemorragias.

Difusión:

- Diagnóstico precoz
lesiones isquémicas.

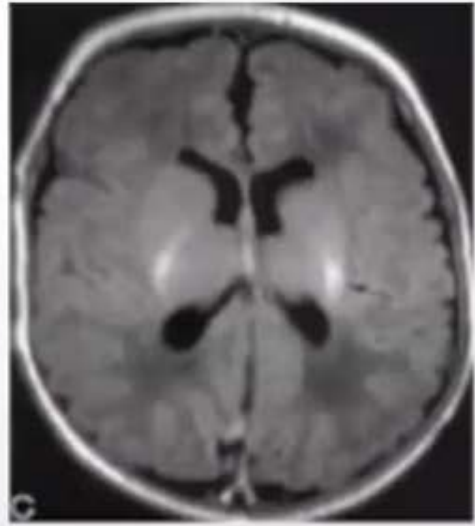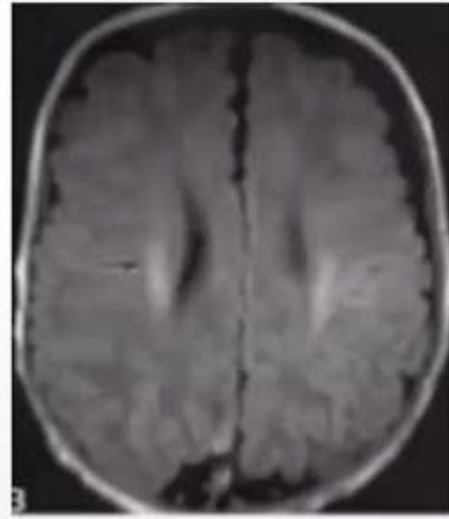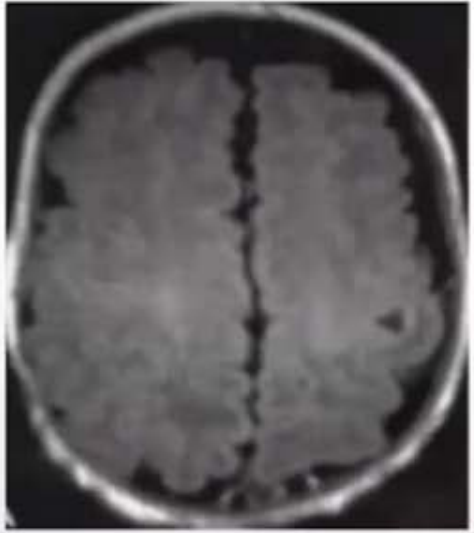Sagital T1



Estructuras de línea media:

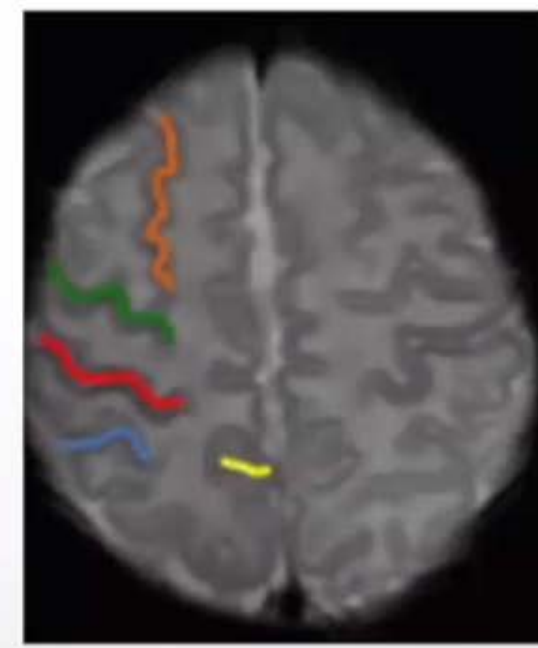
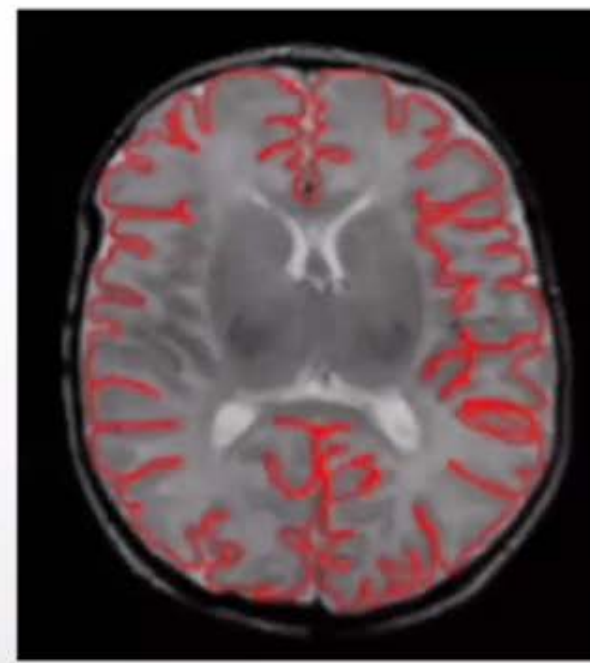
- Cuerpo calloso, hipófisis, hipotálamo, tronco encefálico, cerebelo.
- Zona lateral hemisferios cerebrales, cisura de Silvio.
- Localizador para secuencias axiales y coronales adicionales.

Axial T1



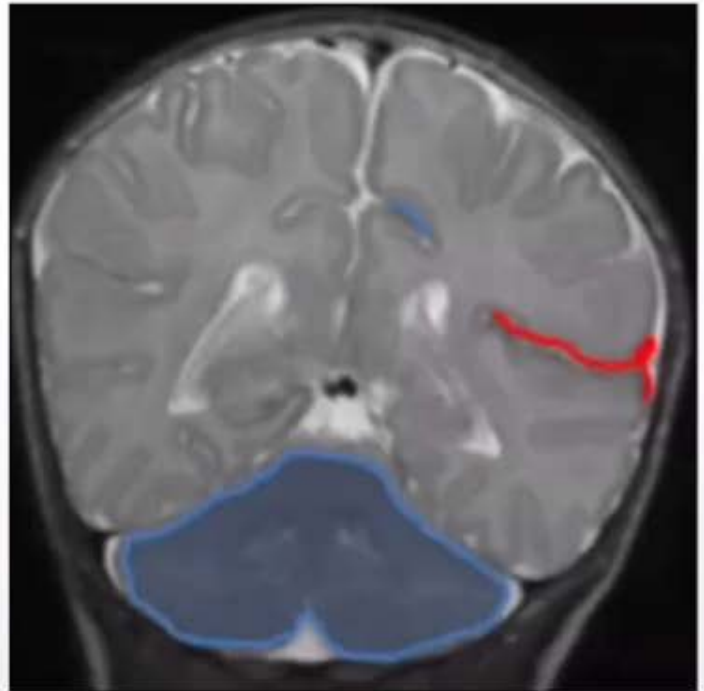
Cambios madurativos, mielinización.

Axial T2



Corteza: sulcación, circunvoluciones

Coronal T2



Cerebelo, lóbulo temporal, base cráneo.

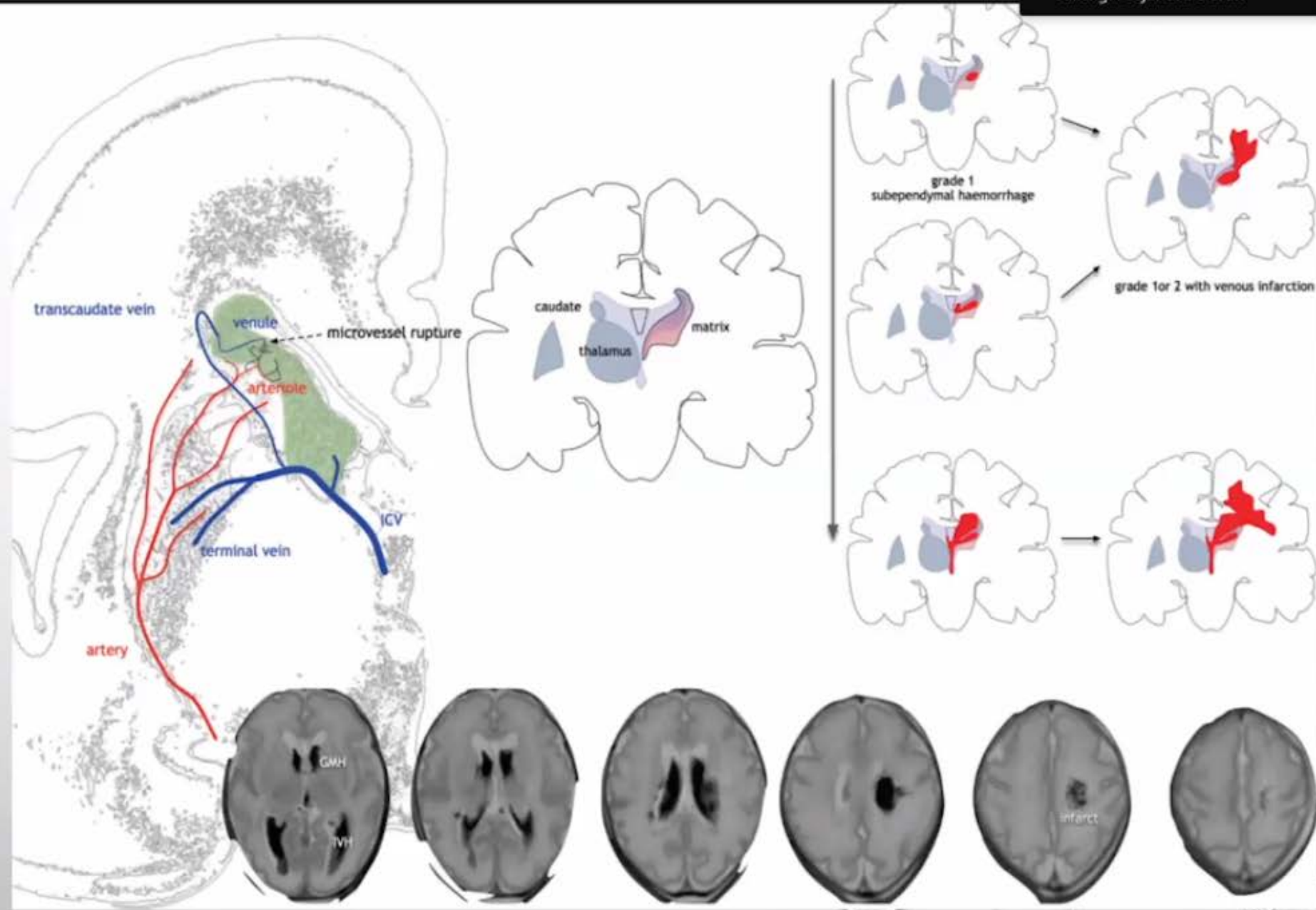
- ▶
- ◀
- ✎
- 📊
- ☰
- 🖥️

APLICACIONES CLÍNICAS

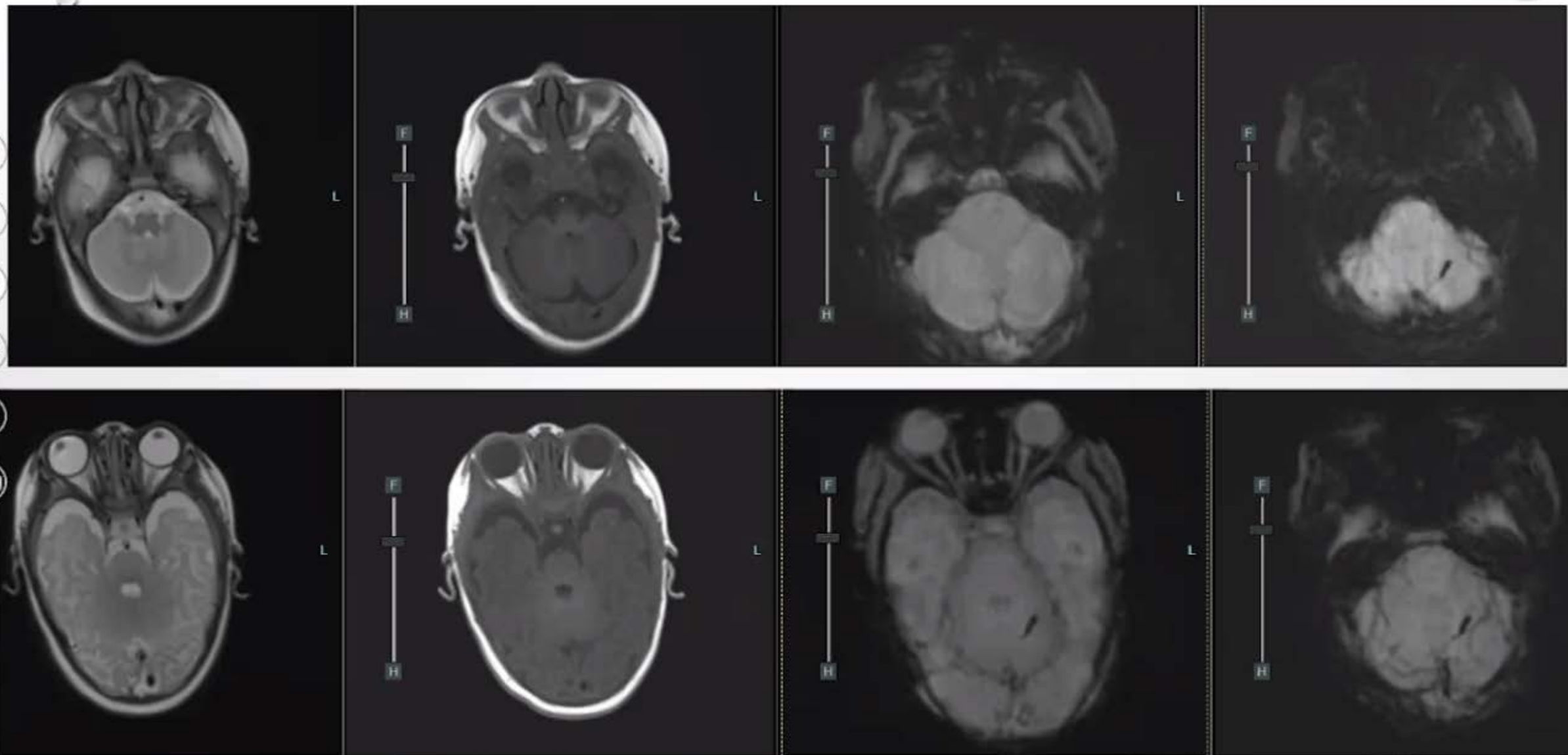


HEMORRAGIA MATRIZ GERMINAL

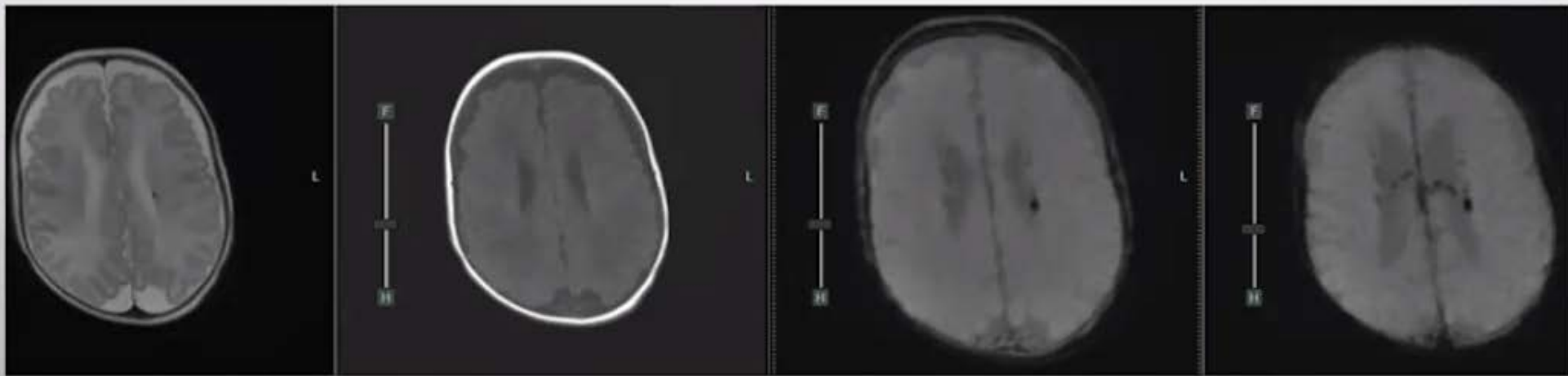
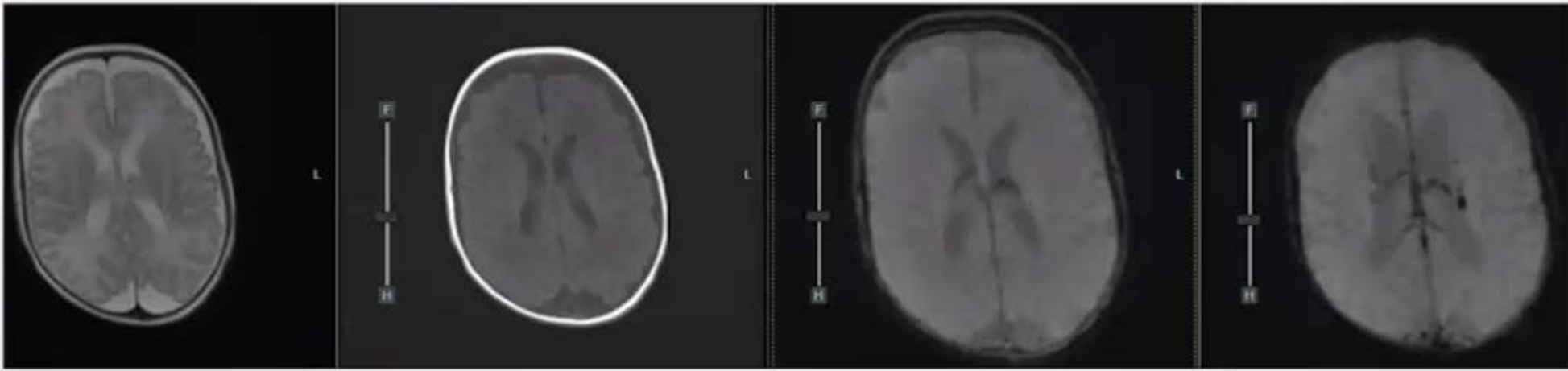
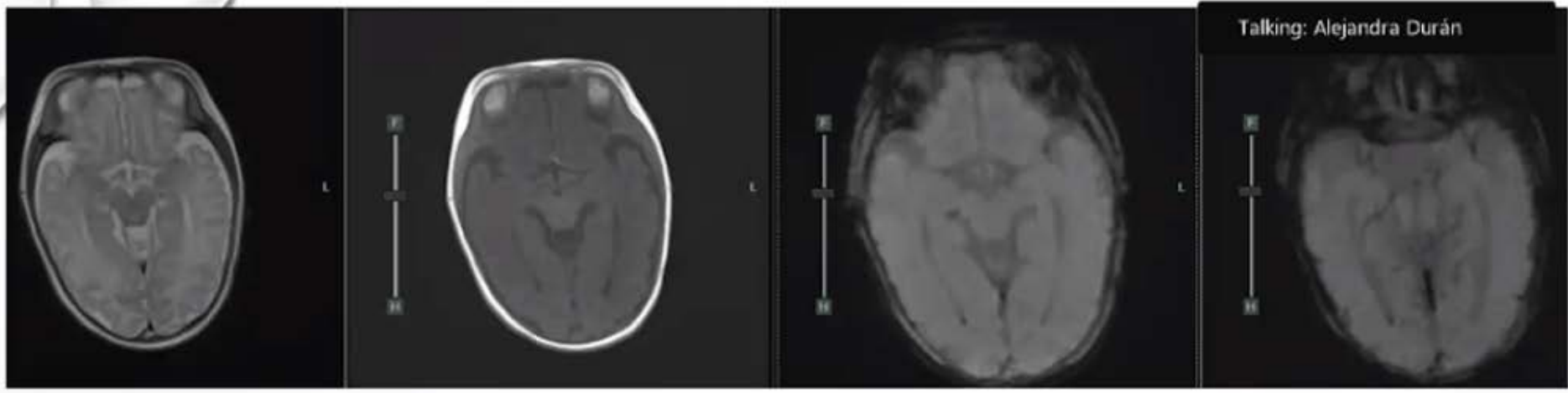




RNPT 29 semanas, ant. perinatal de HIA cr y P-E sobreagregada



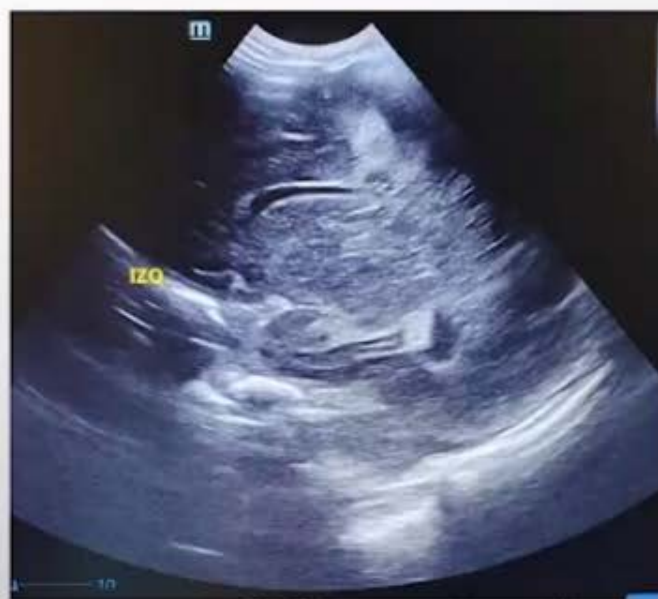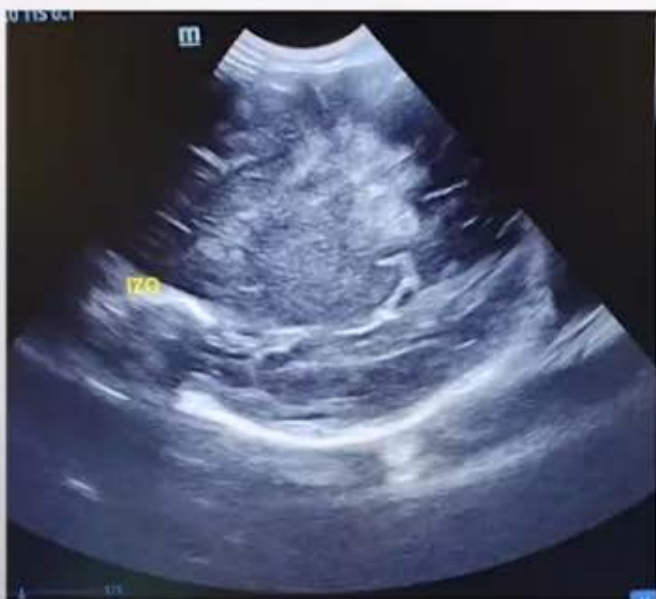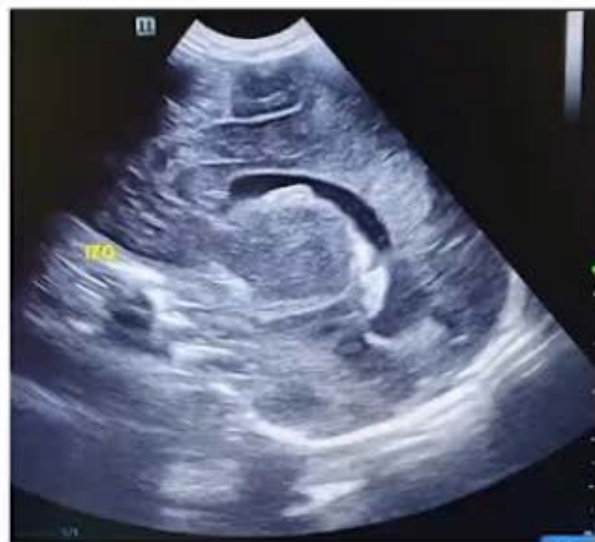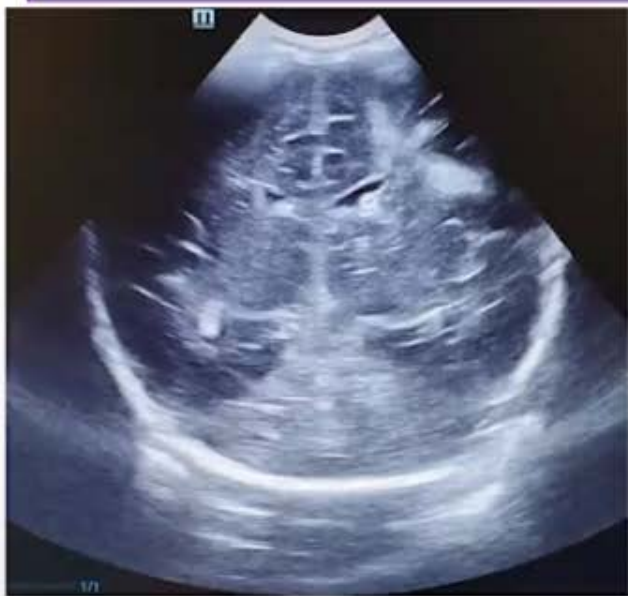Talking: Alejandra Durán

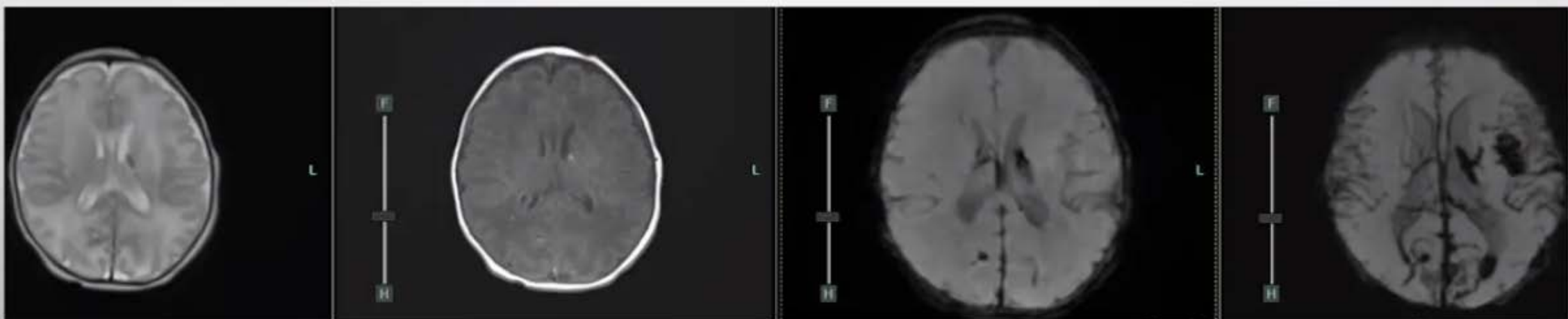
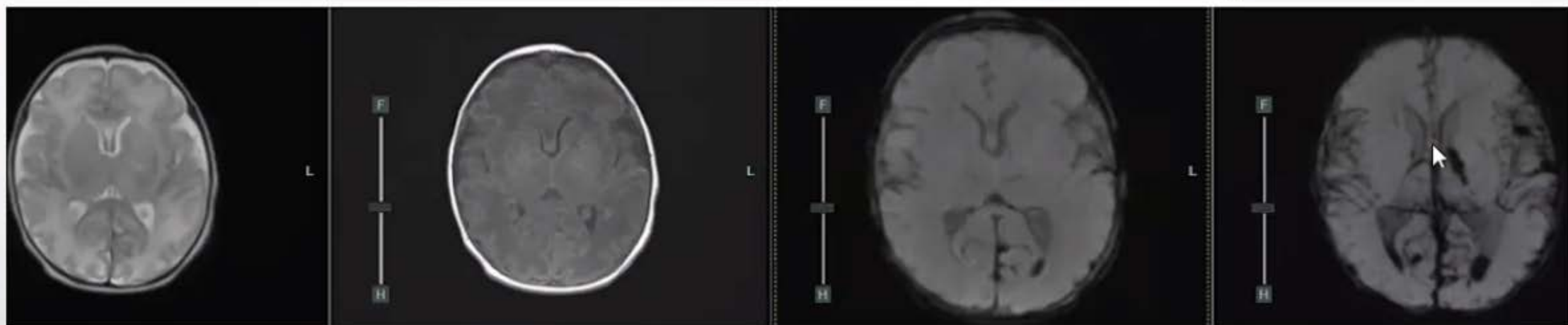
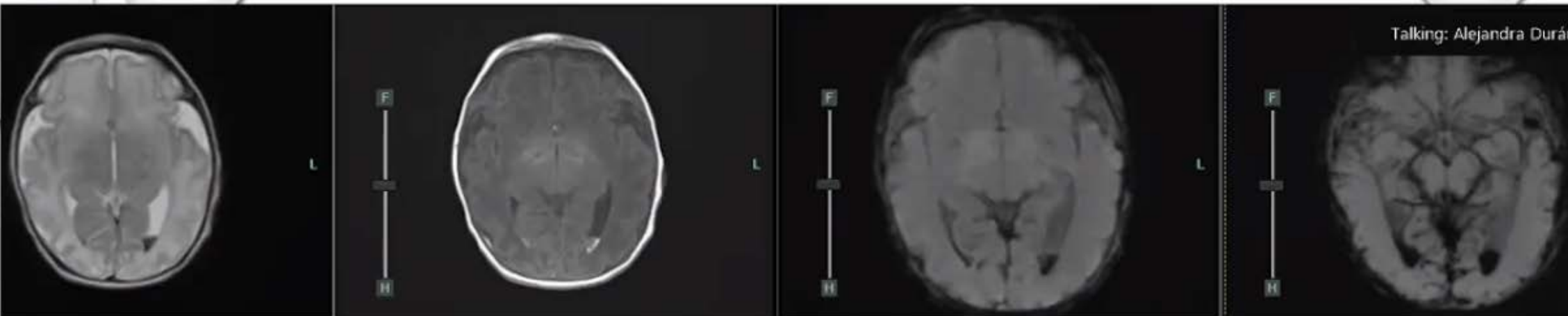


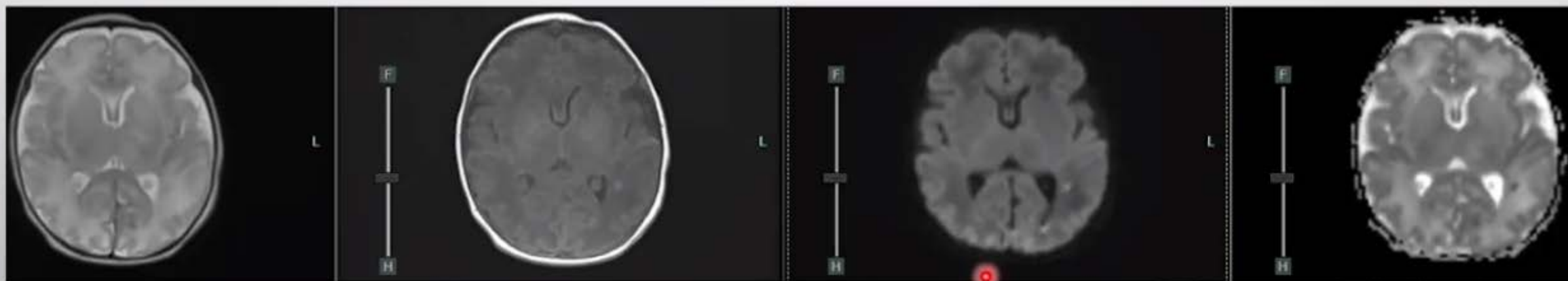
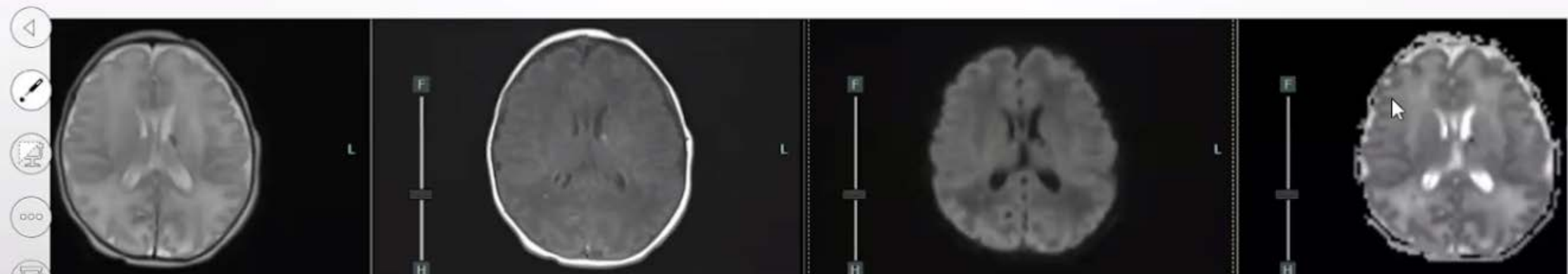
RNPT 34 semanas, ant. perinatal DMG

Talking: Alejandra Durán

Sign in 00:38:18



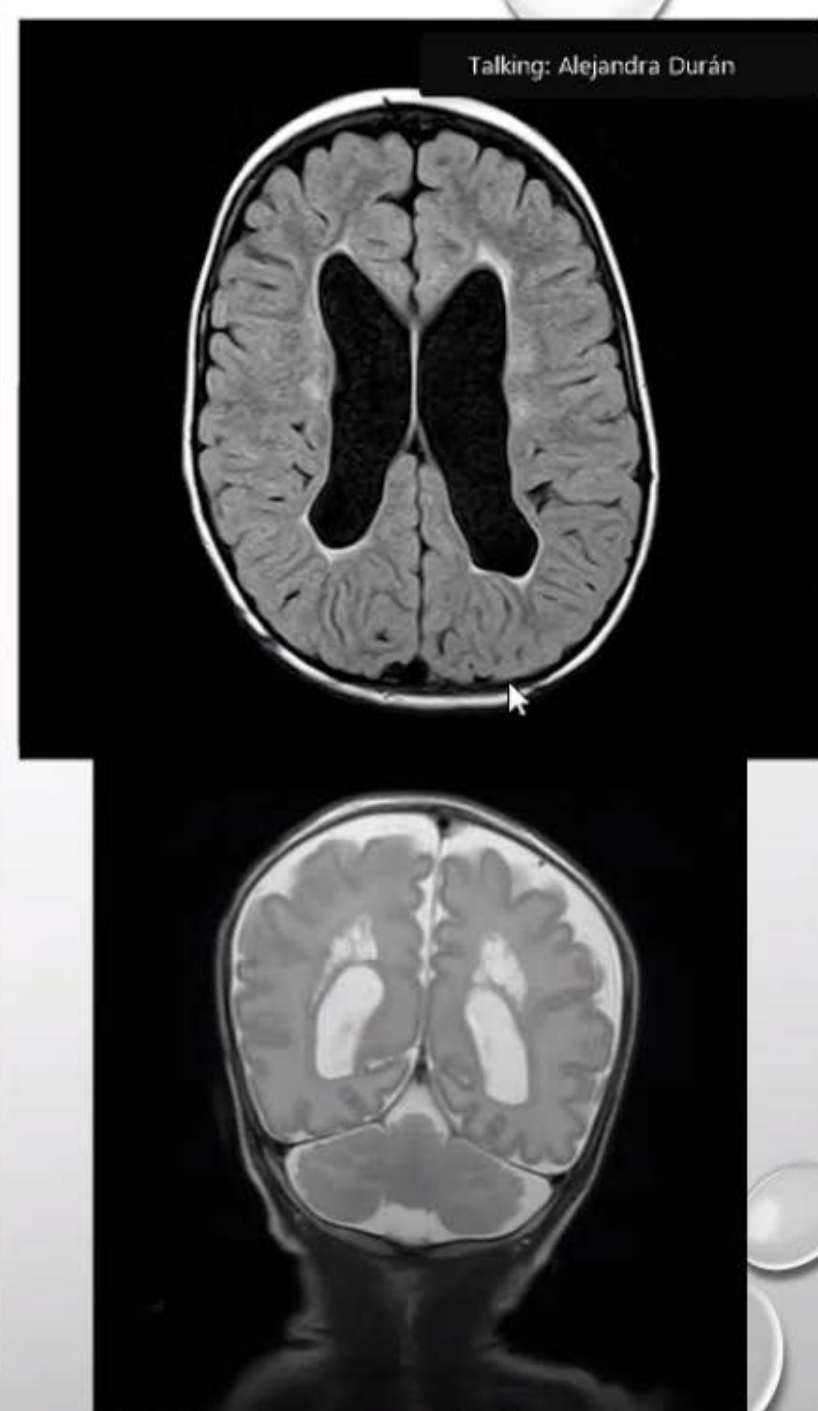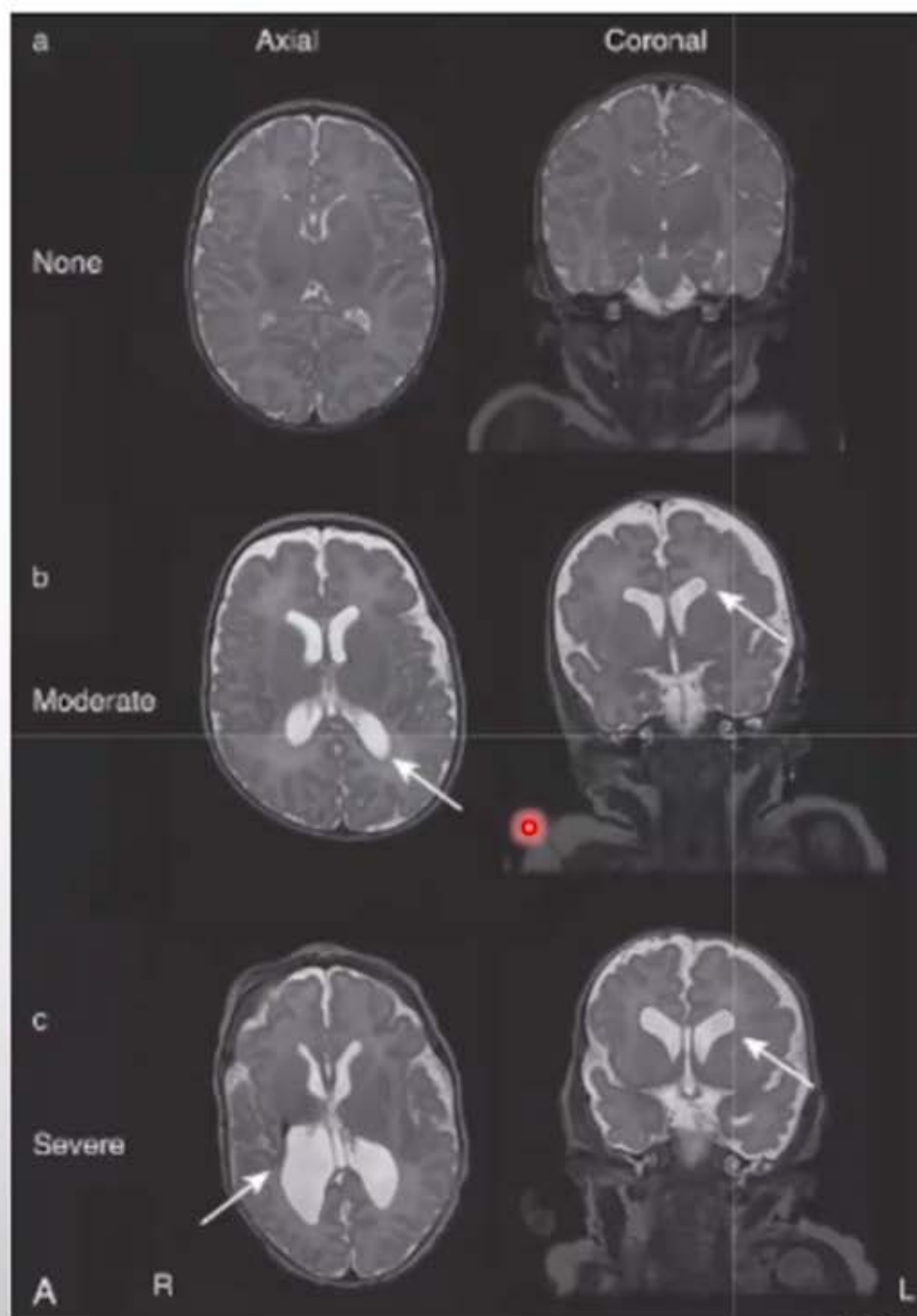




LESIÓN SUSTANCIA BLANCA POR PREMATUREZ

2

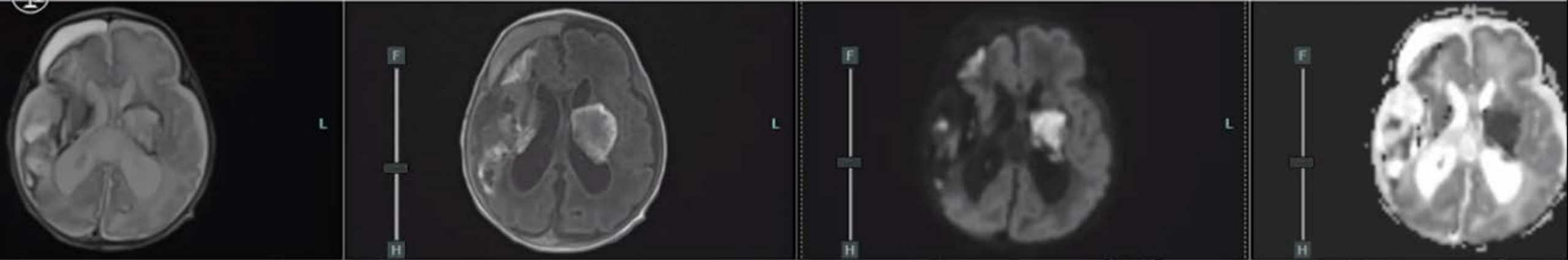
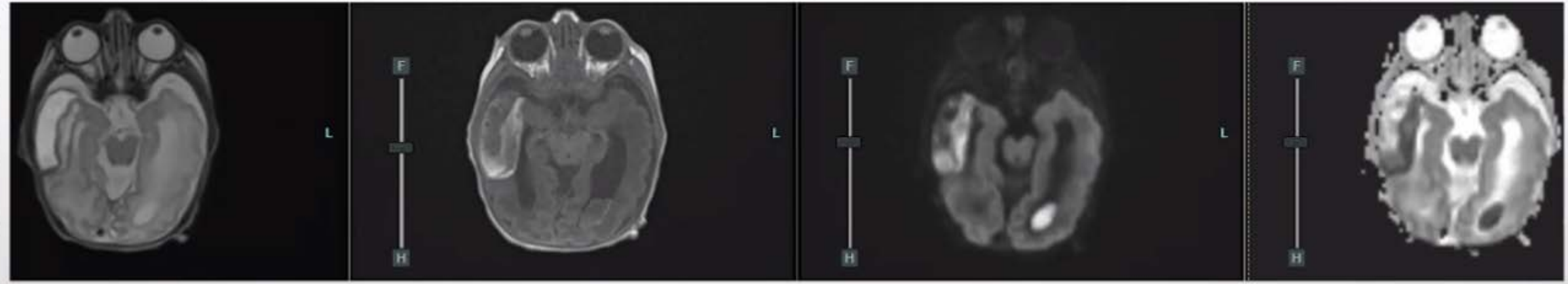
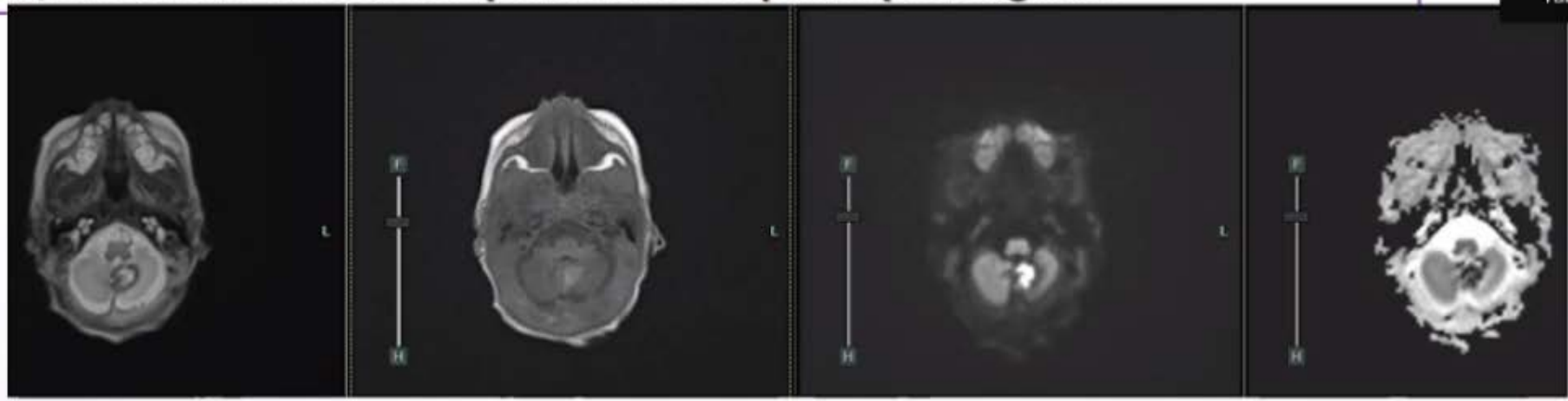
Alteraciones de sustancia blanca



RNPT 28 semanas, PEG: EMH severa con períodos de hipoxia prolongados

Talking: Alejandra Durán

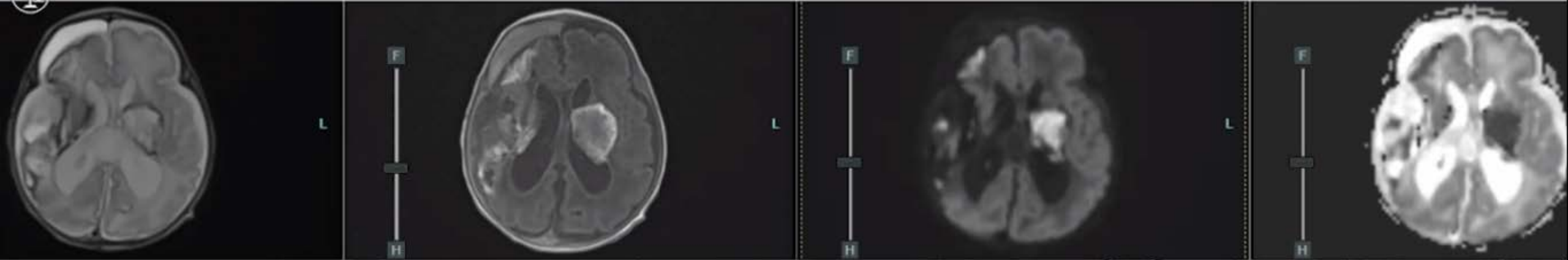
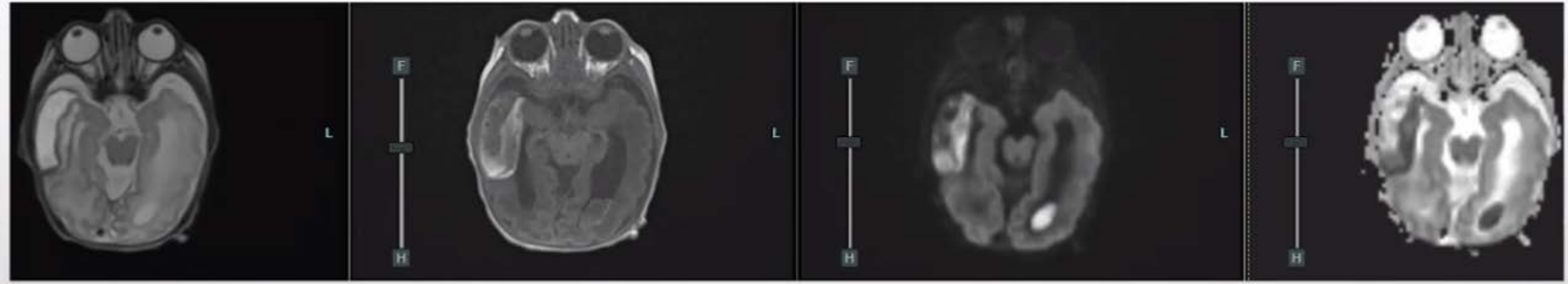
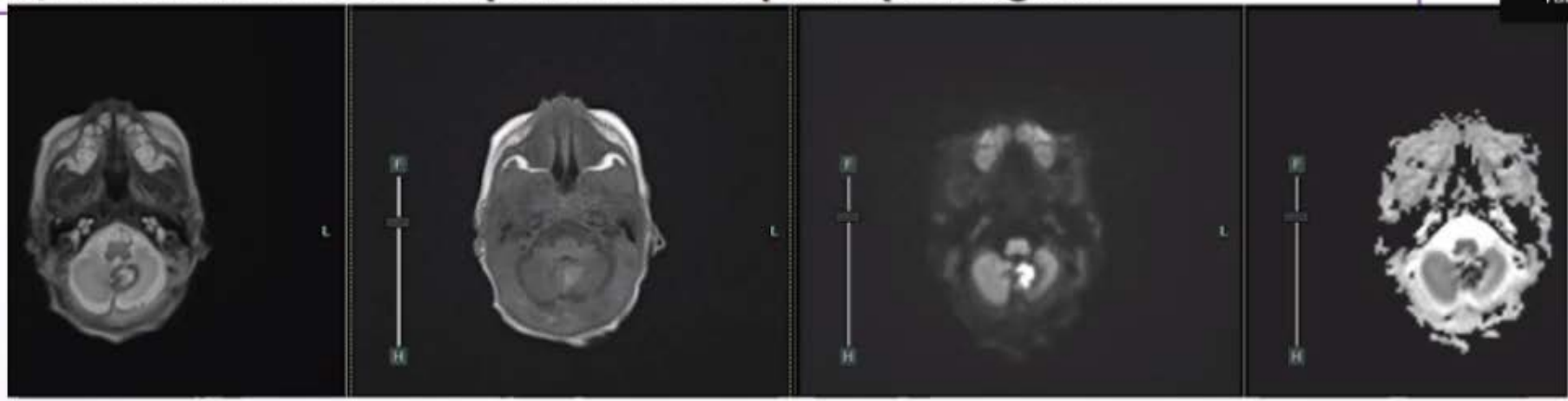
A vertical column of navigation icons for a medical viewer, including symbols for play, back, forward, zoom, and search.

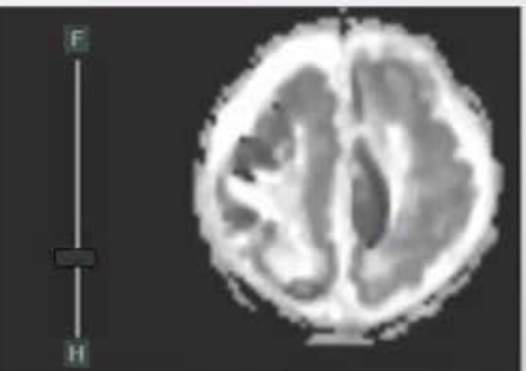
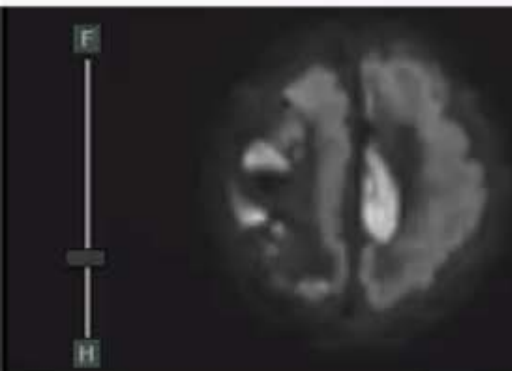
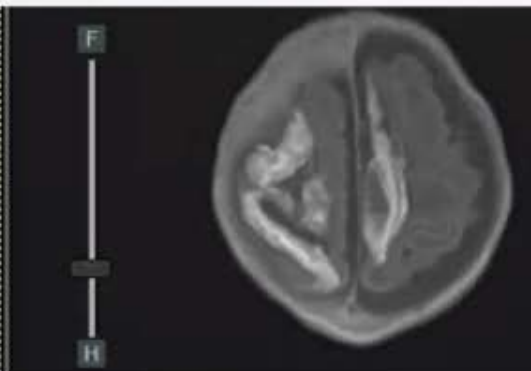
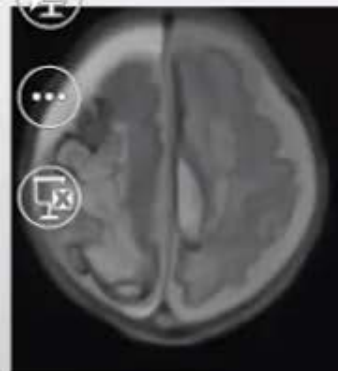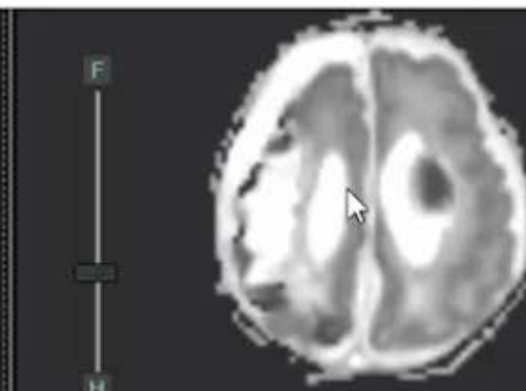
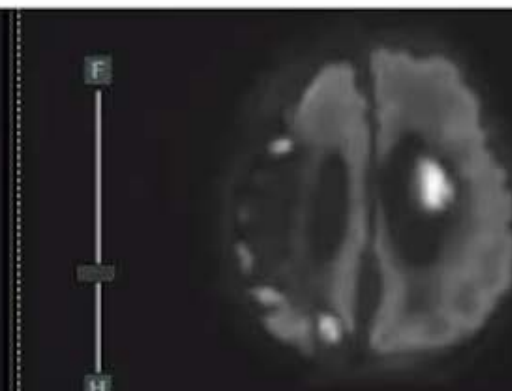

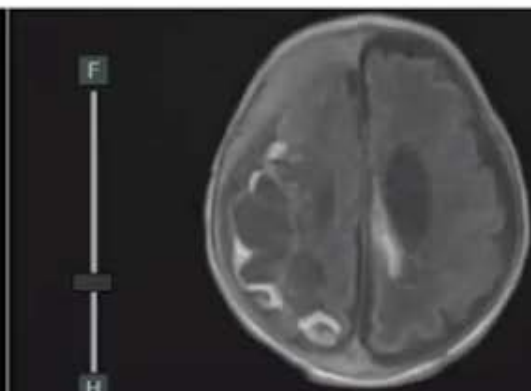
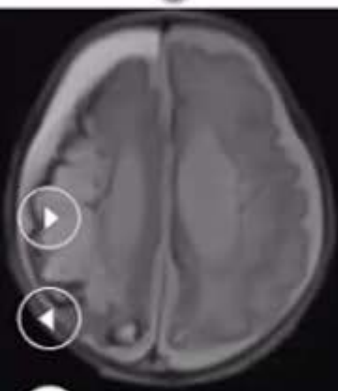RNPT 28 semanas, PEG: EMH severa con períodos de hipoxia prolongados

Talking: Alejandra Durán

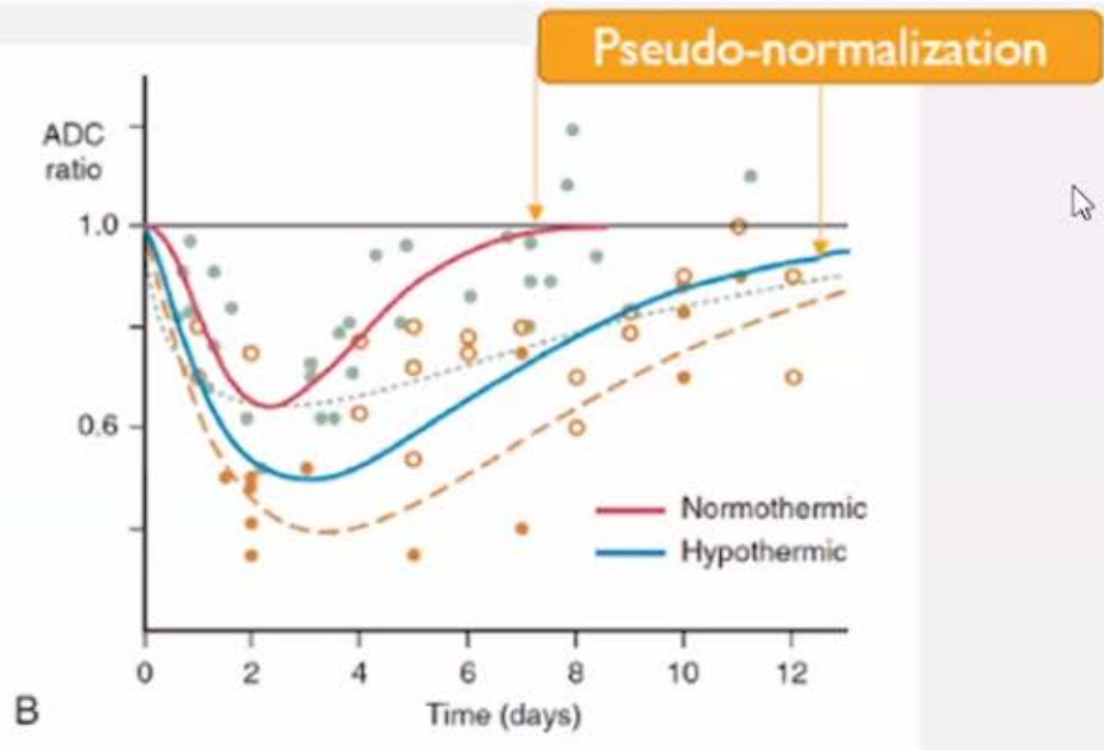
A vertical column of navigation icons for a medical viewer, including a play button, a back arrow, a zoom-in icon, a search icon, and a refresh icon.





¿Cuándo realizar la RM?

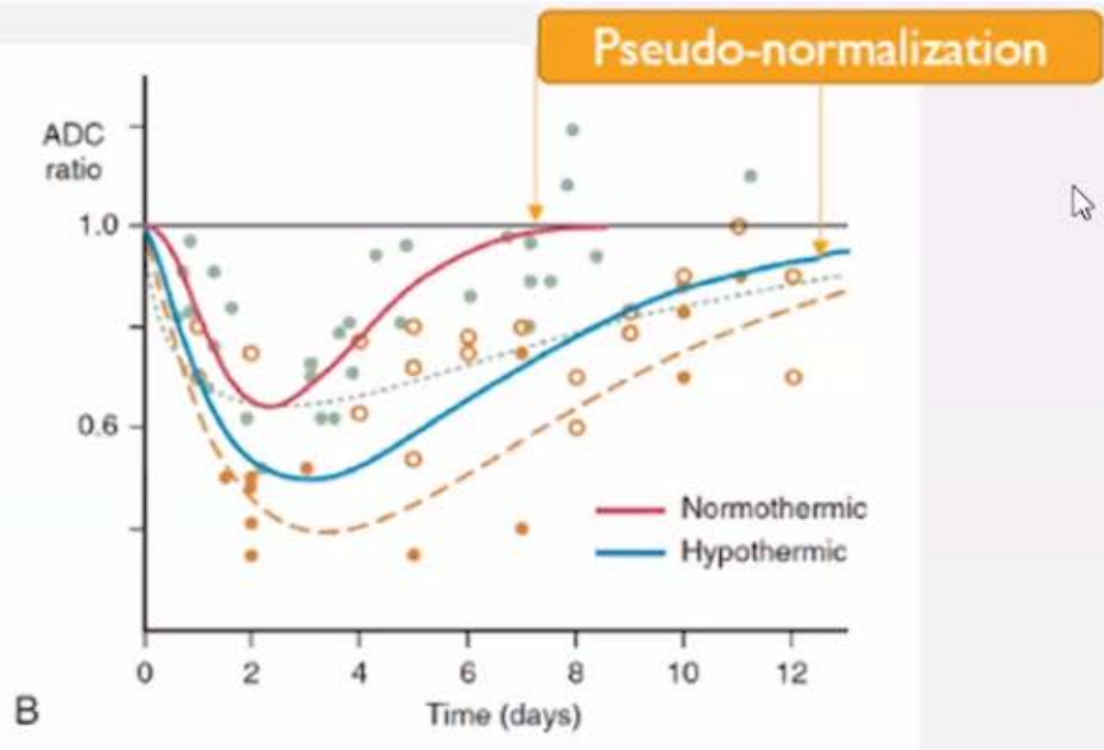
- Confirm the diagnosis, determine the extent of injury, and outcome tool.
- Diffusion-weighted imaging (DWI) is optimally obtained between 3 - 5 DOL.
- DWI detects abnormalities in free-water diffusion.
- The ADC or average diffusivity map (D_{av}) is a quantitative water diffusion map restricted diffusion as areas of diminished signal intensity.



(DWI) in Day 3-5 / (T1/T2) in Day 10-14

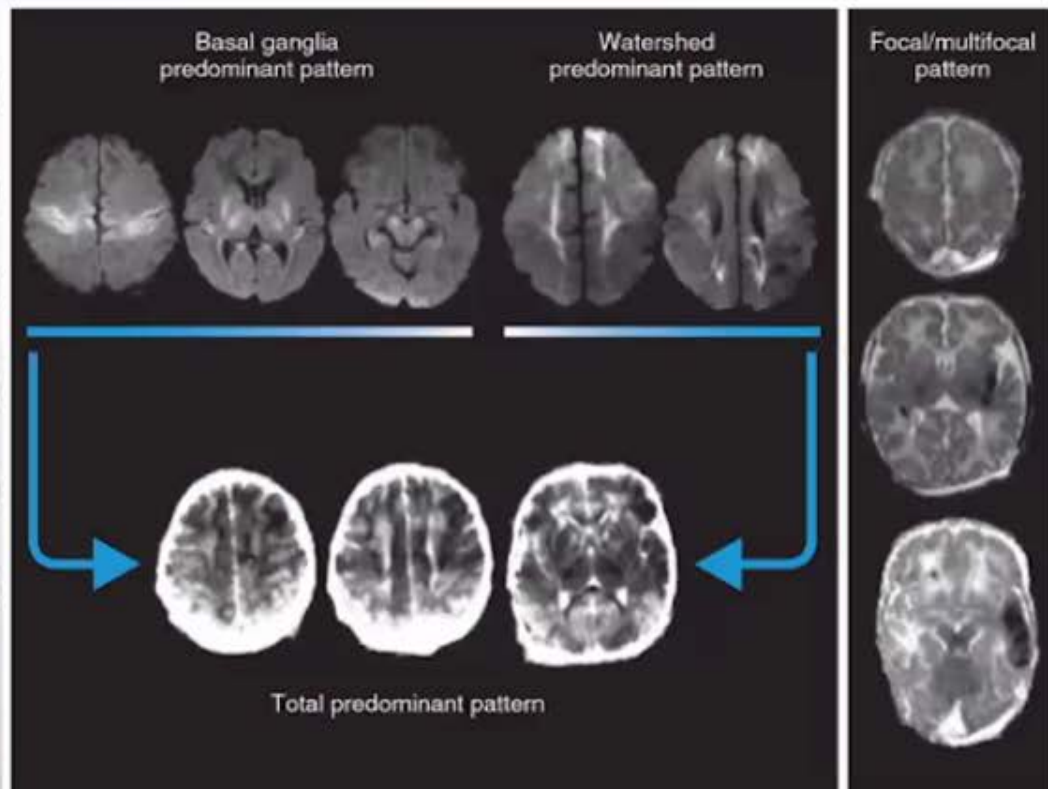
¿Cuándo realizar la RM?

- Confirm the diagnosis, determine the extent of injury, and outcome tool.
- Diffusion-weighted imaging (DWI) is optimally obtained between 3 - 5 DOL.
- DWI detects abnormalities in free-water diffusion.
- The ADC or average diffusivity map (D_{av}) is a quantitative water diffusion map restricted diffusion as areas of diminished signal intensity.



(DWI) in Day 3-5 / (T1/T2) in Day 10-14

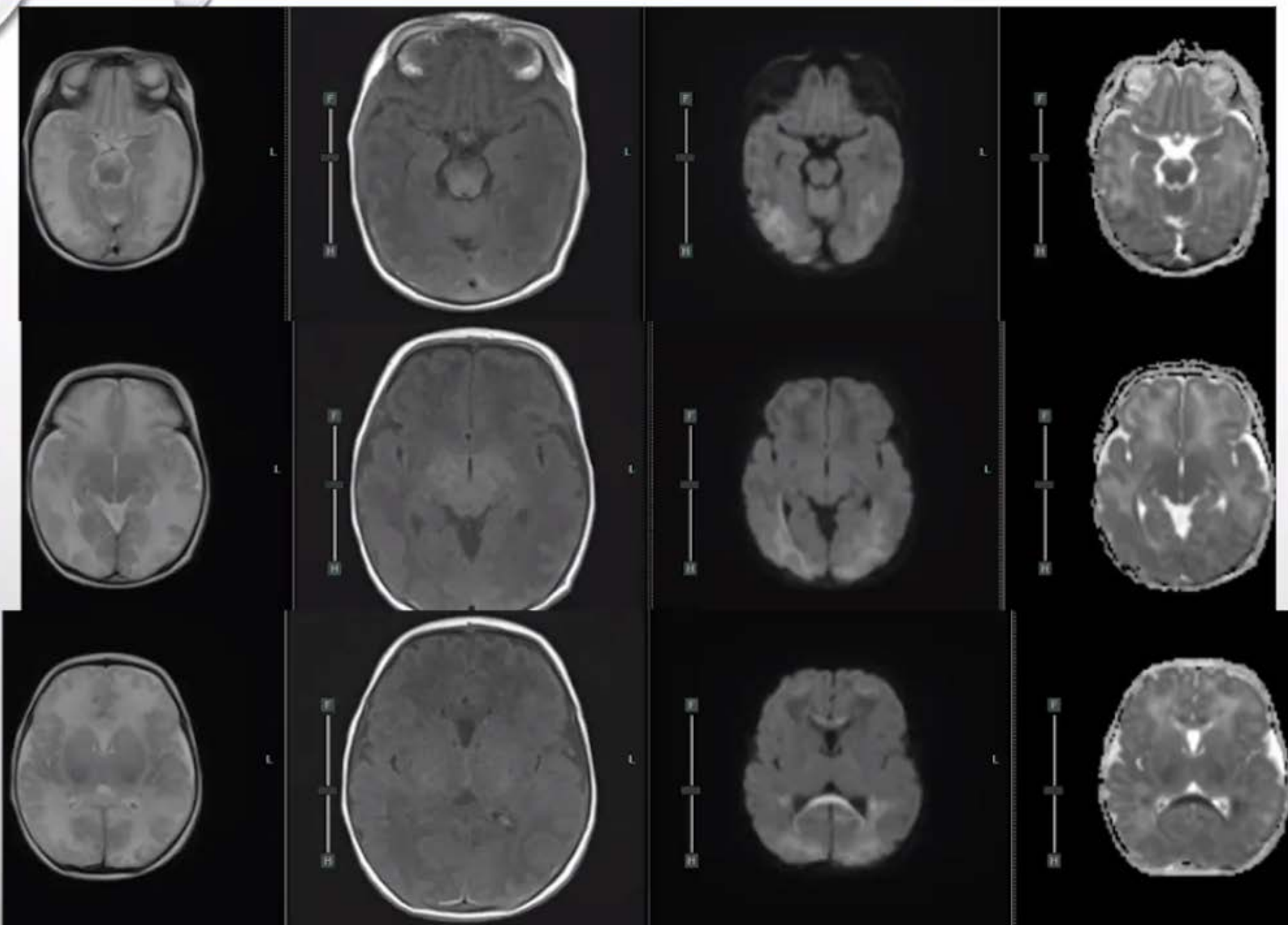
Patrones de lesión: Secuencia Difusión



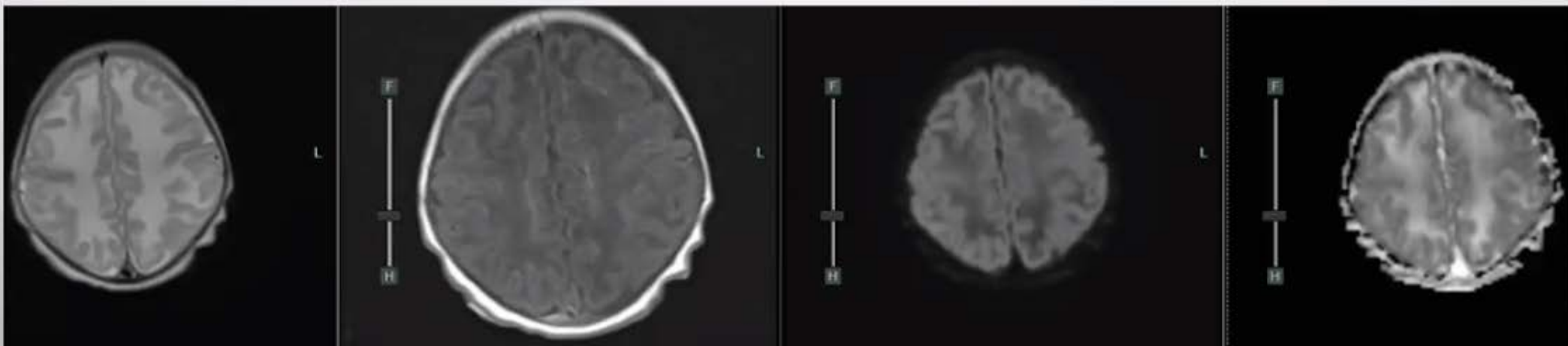
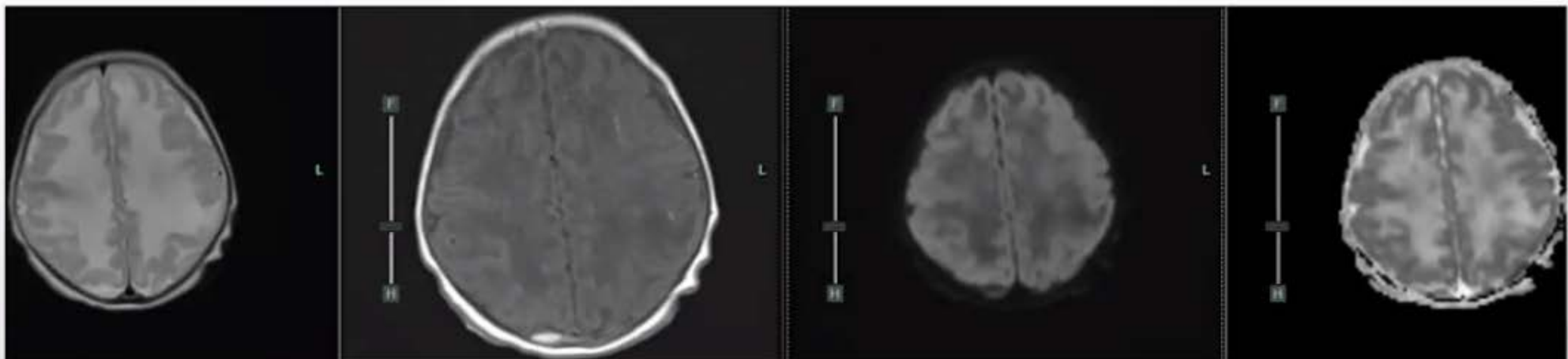
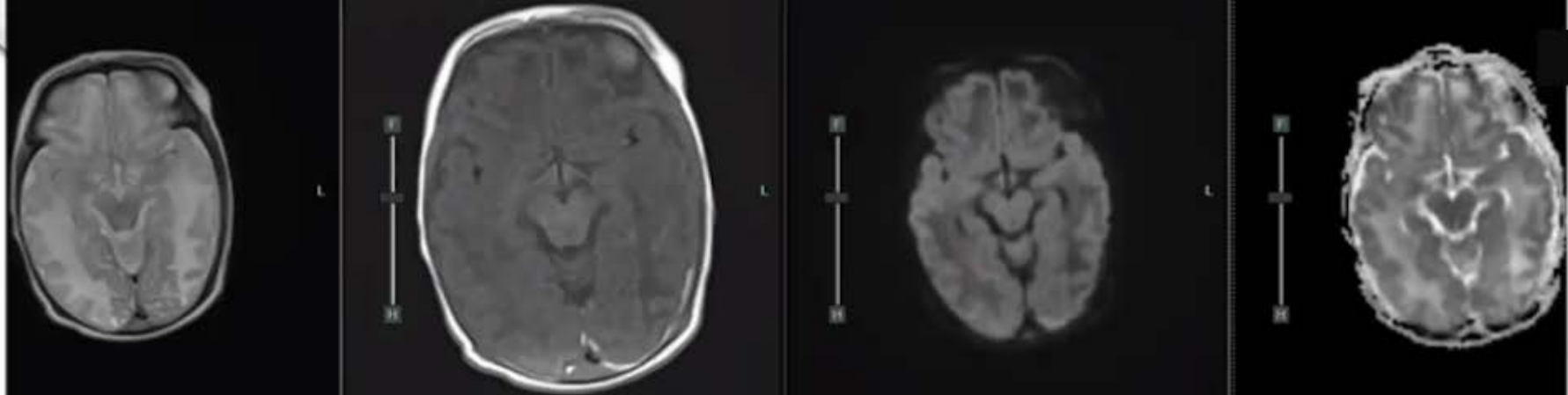
	Basal ganglia/Thalamic pattern (BGT)	Watershed pattern (WS)
Mechanism of injury	Acute profound asphyxia/ Acute near total asphyxia	Prolonged partial asphyxia
Area of affected	Bilateral central grey nuclei and periolantic cortex (highest metabolic needs)	Parasagittal white matter in the vascular watershed area
Etiology	Acute sentinel event: ruptured uterine, placental abruption, prolapse cord	More common with history of hypotension, infection, hypoglycemia
Associated disabilities	Motor and cognitive disabilities	Cognitive deficits, behavioural issue, learning disabilities

EHI: Patrón de territorio vascular limítrofe: 72 hrs. de vida

Talking: Alejandra Durán

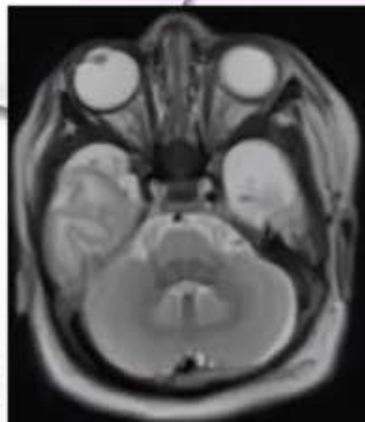


14 días de vida

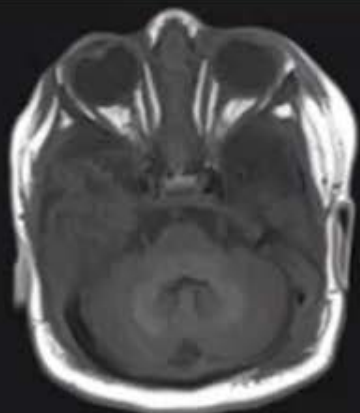

Patrón Núcleos de la base: 72 hrs. de vida

Talking: Alejandra Durán

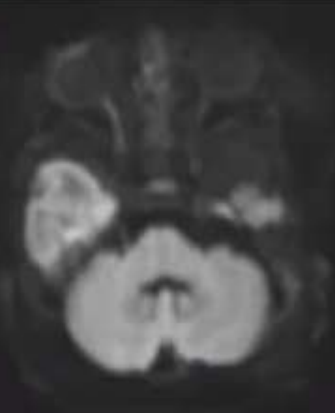


F



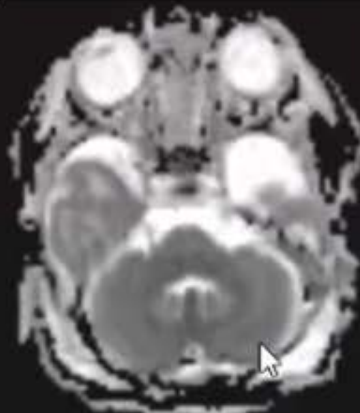
H

F

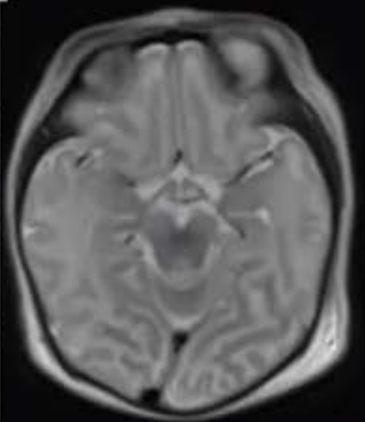


H

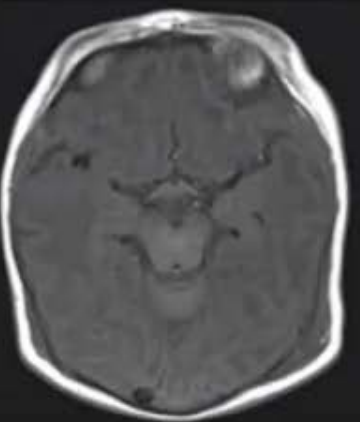
F



H

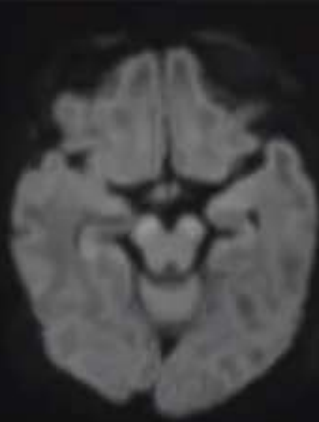


F



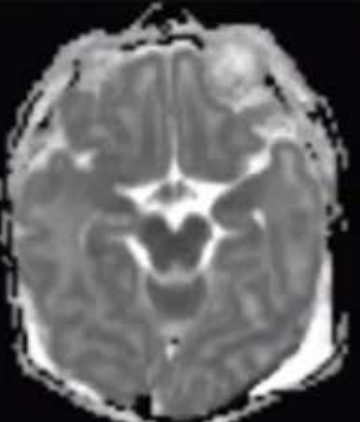
H

F

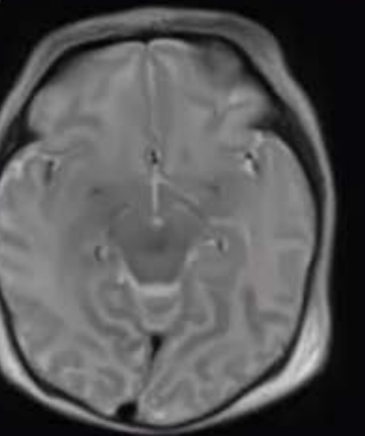


H

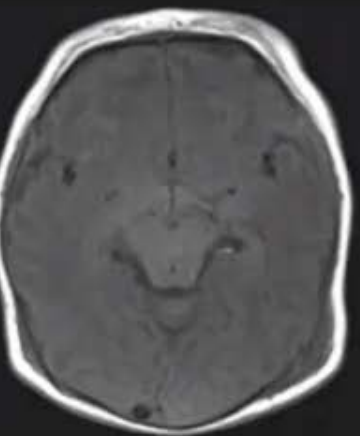F



H

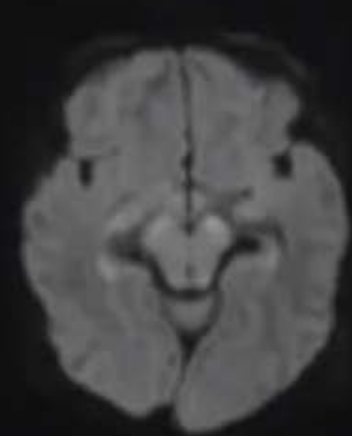


F



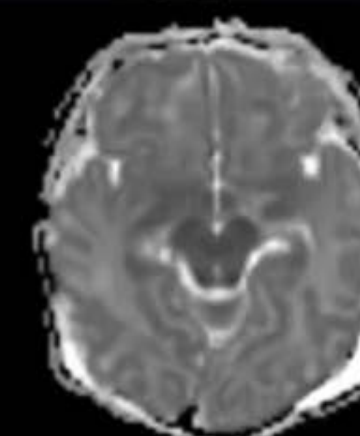
H

F



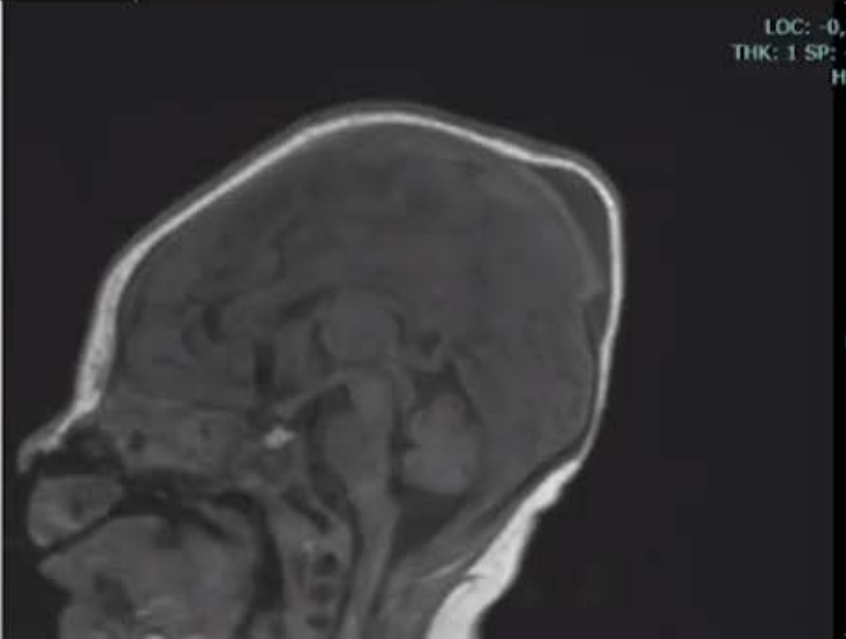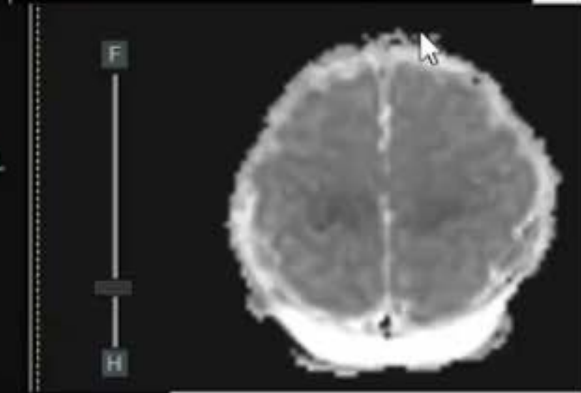
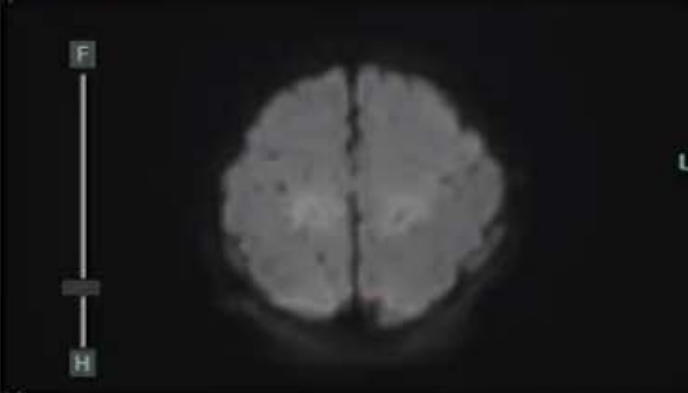
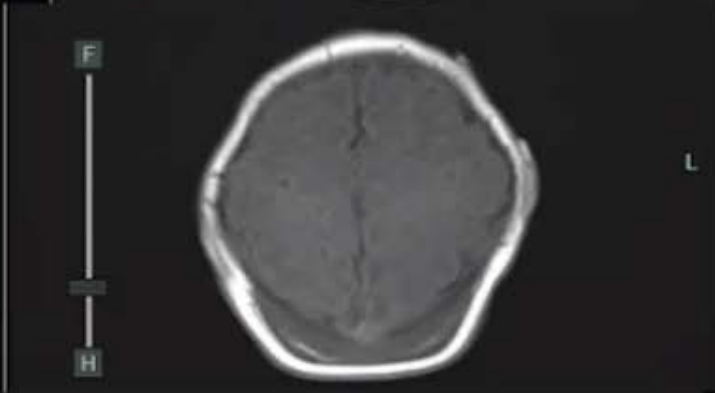
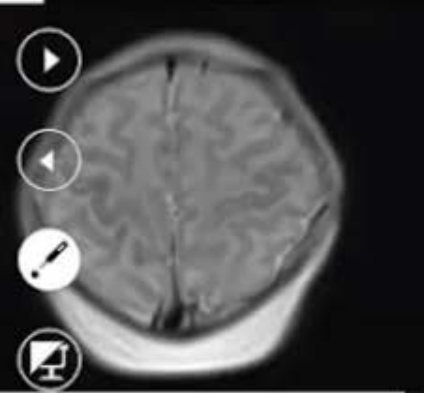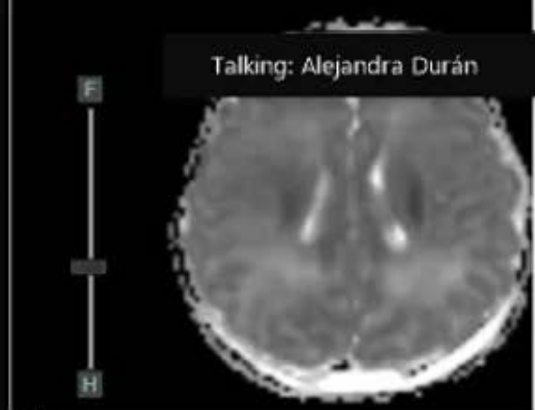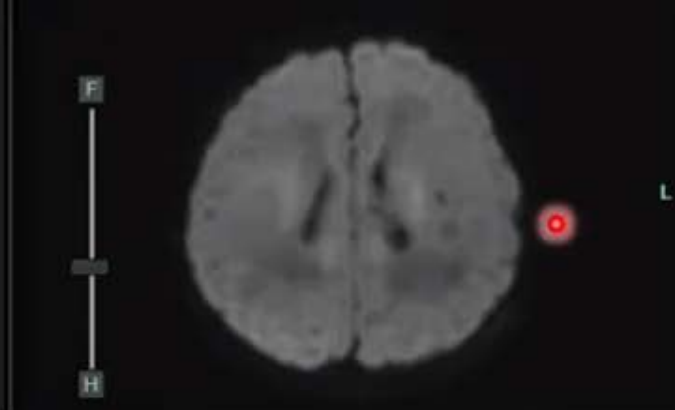
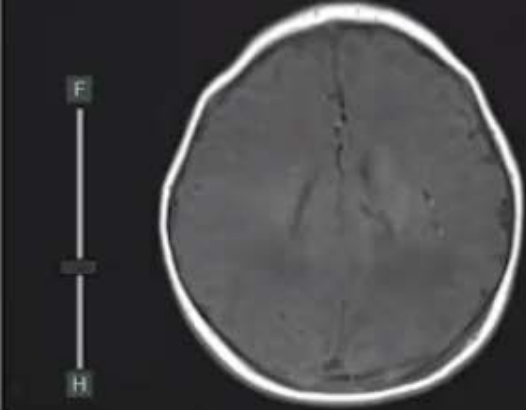
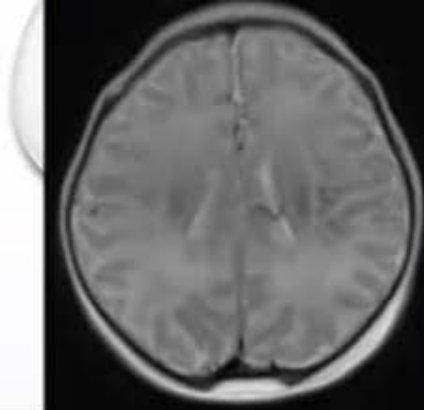
H

F

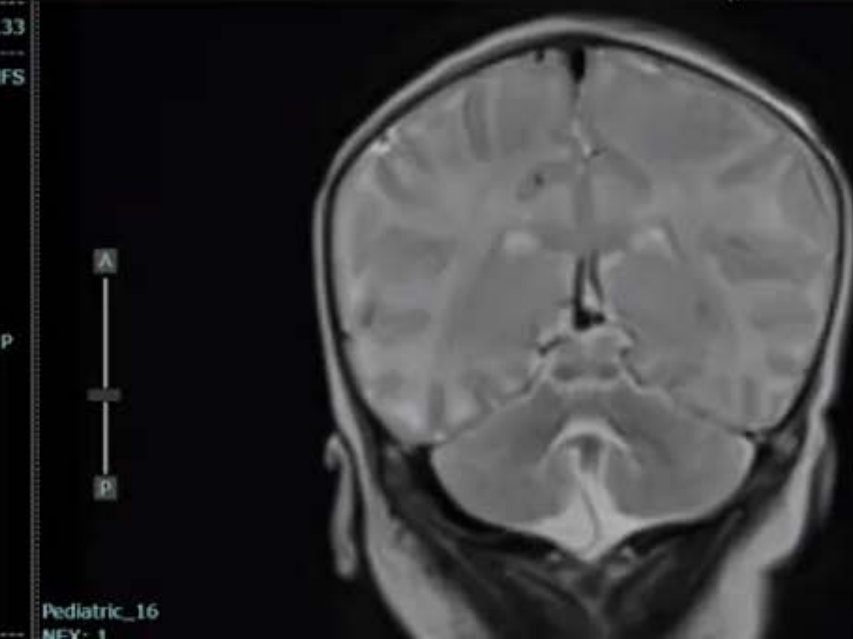


H



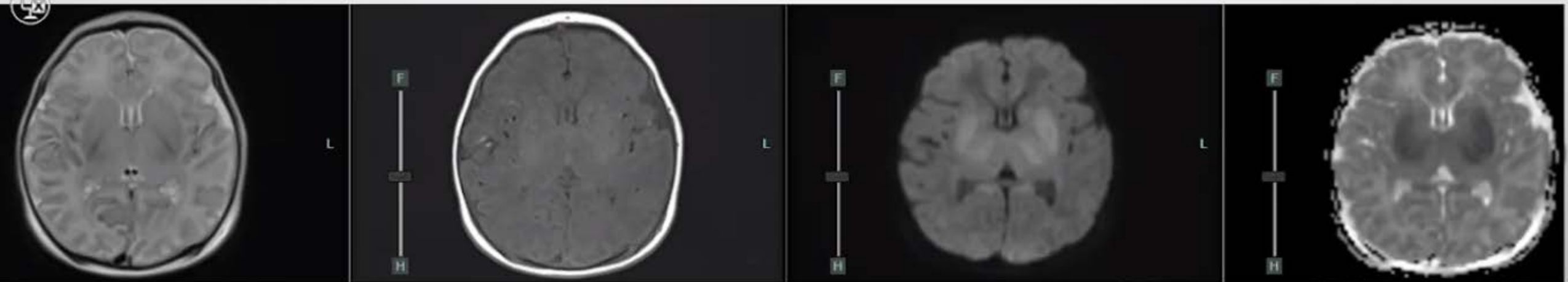
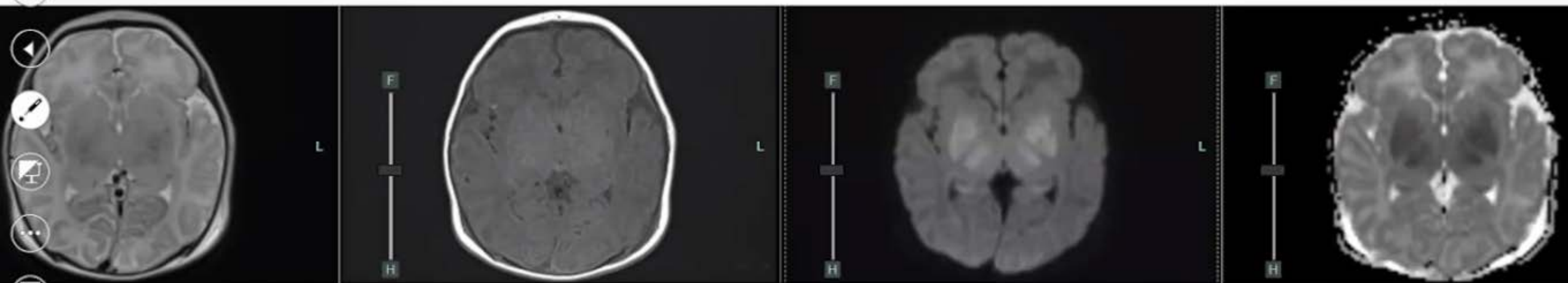
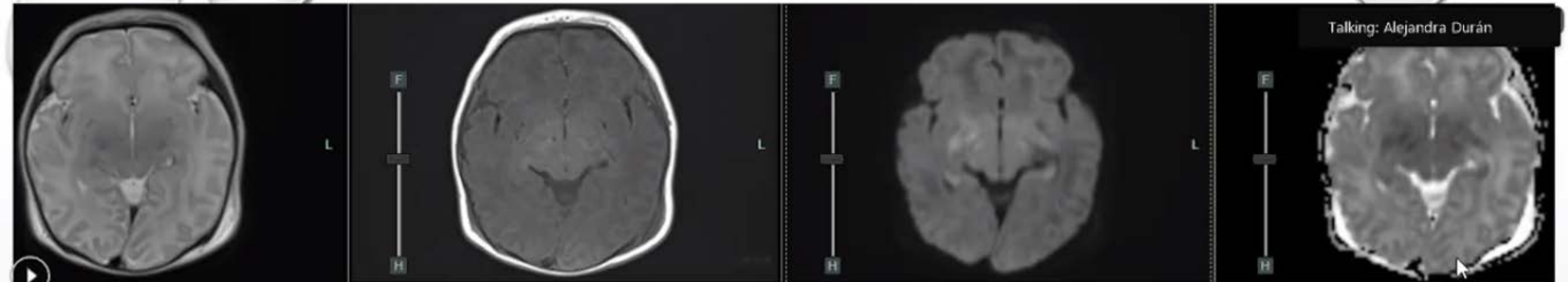


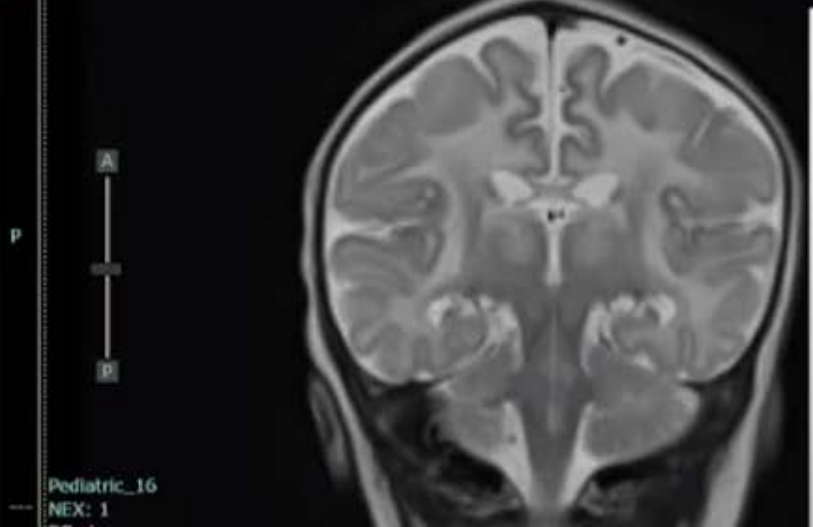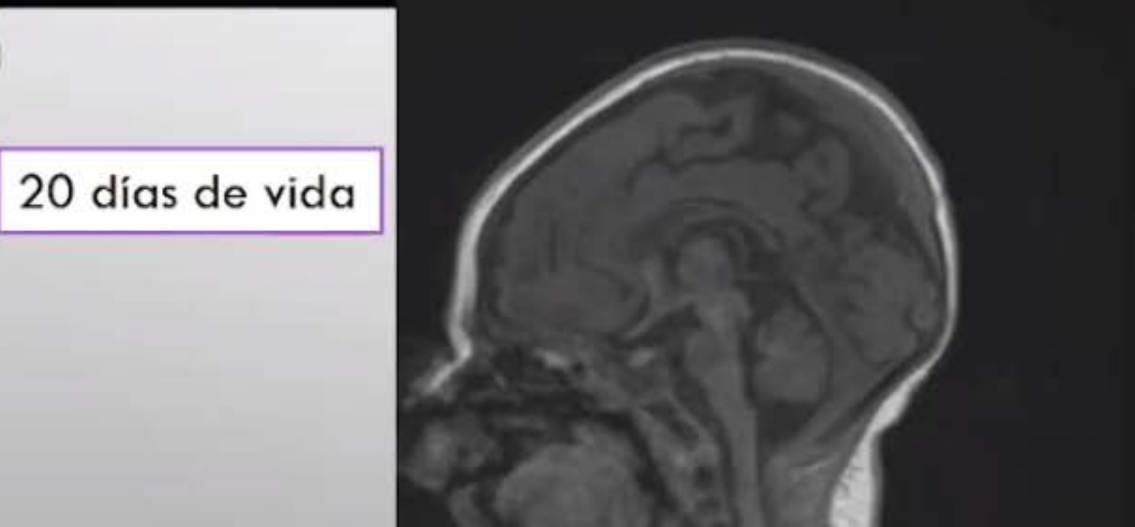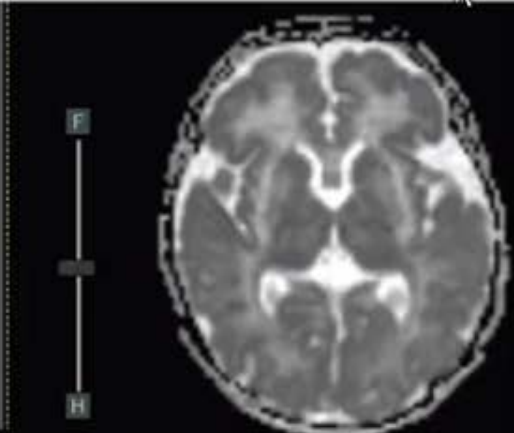
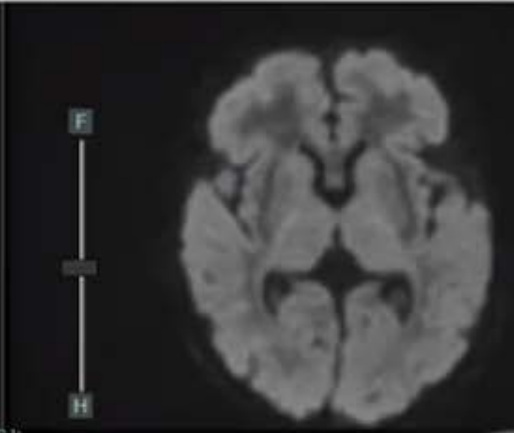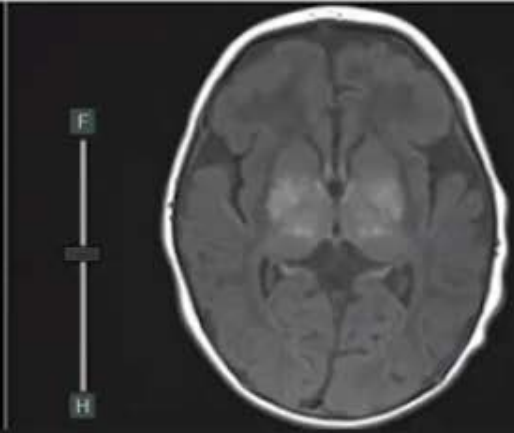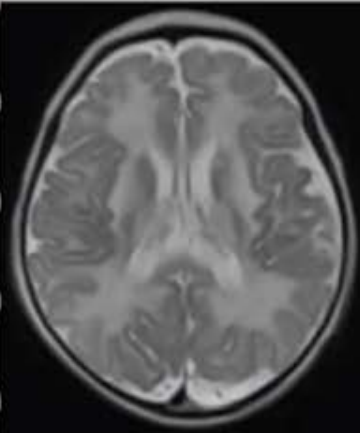
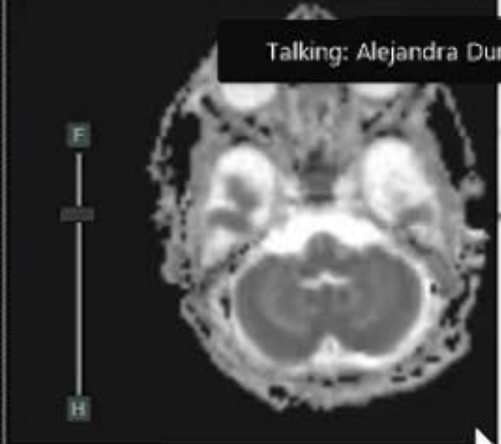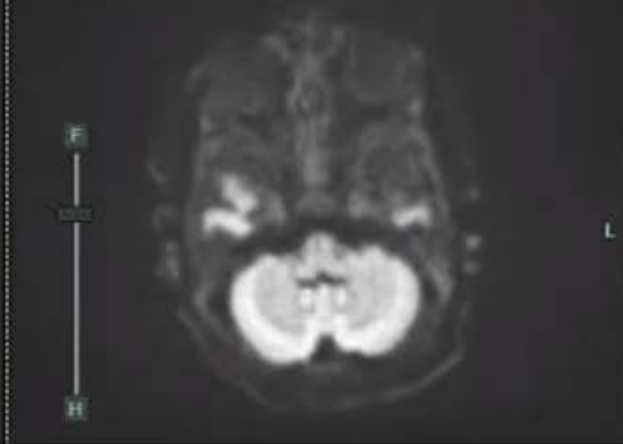
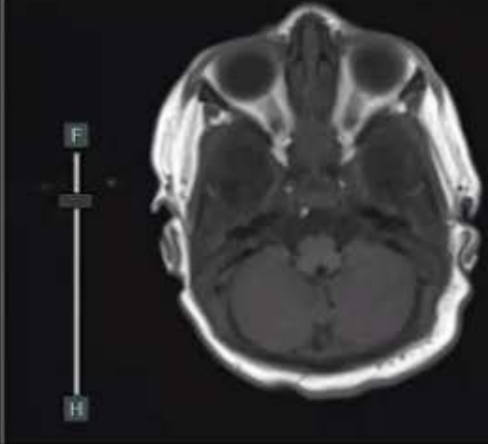
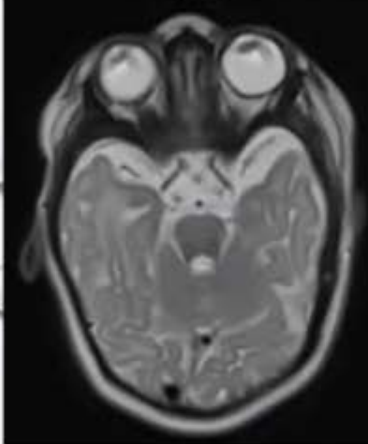
LOC: -0,33
THK: 1 SP: ---
HFS



Pediatric_16
NEY: 1



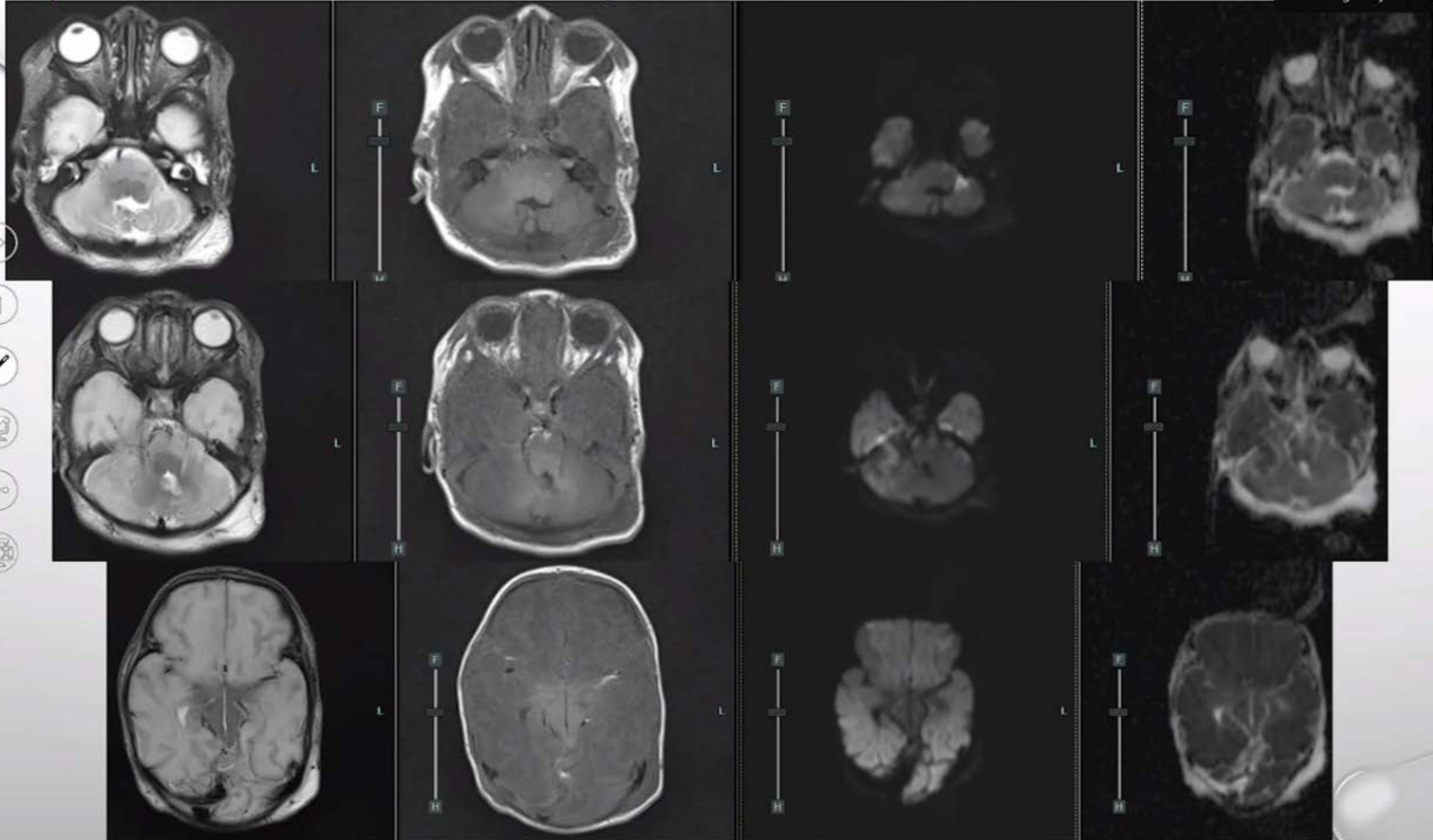


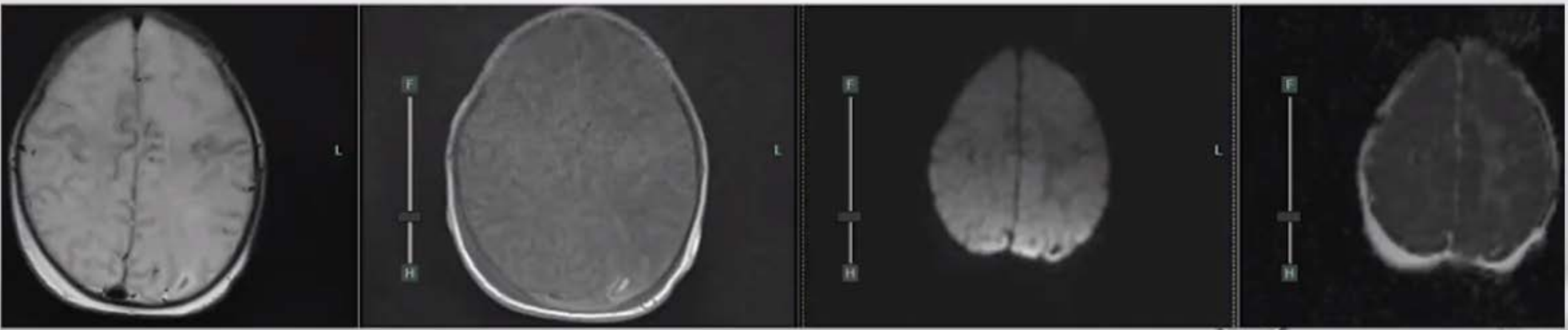
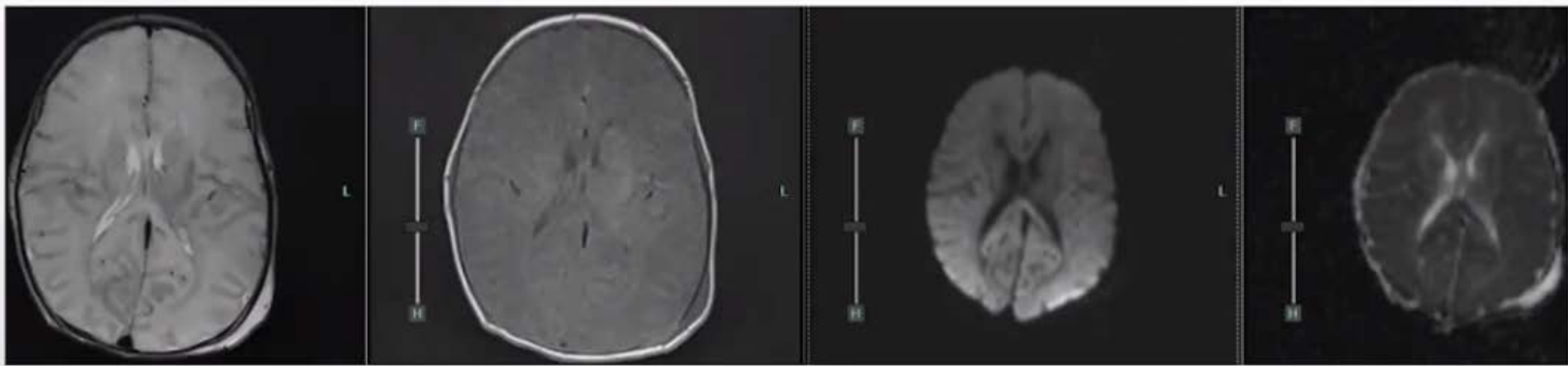
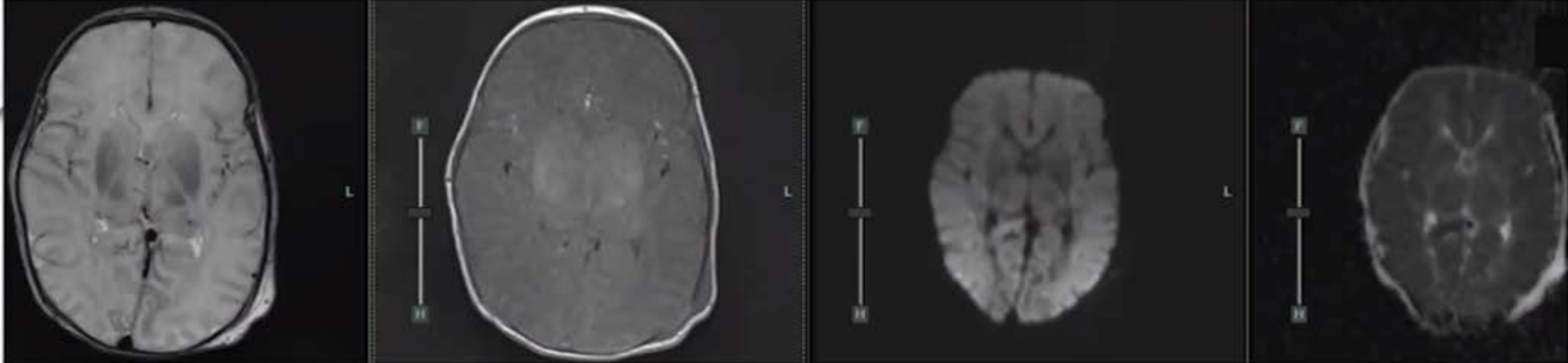


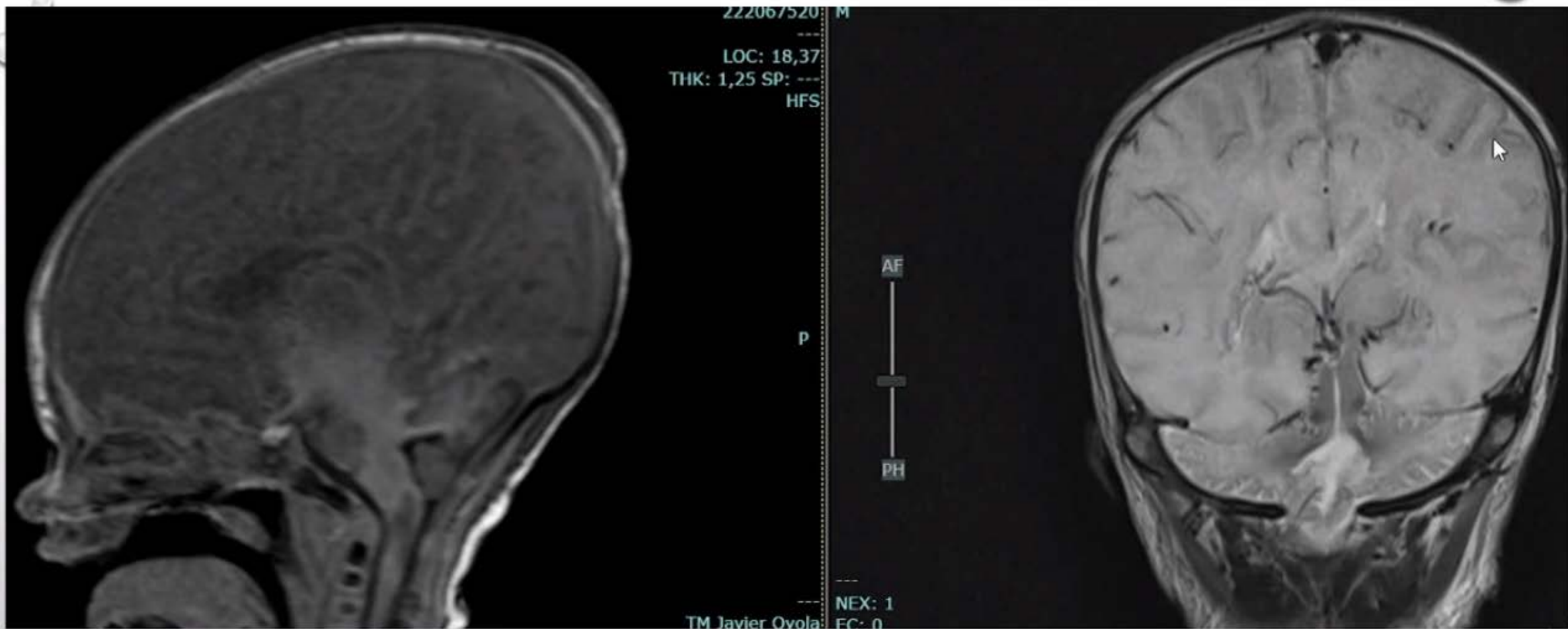
20 días de vida

EHI: Patrón total: 7 días de vida

Talking: Alejandra Durán







FIN